



Radiosurgery Practice Guideline Initiative

Stereotactic Radiosurgery for Patients with **Metastatic Brain Tumors**

Radiosurgery Practice Guideline Report # 5-08

ORIGINAL GUIDELINE: May 2008
MOST RECENT LITERATURE SEARCH: May 2008

This practice guideline, together with a report on “Metastatic Brain Tumor Management” is an original guideline approved by The International RadioSurgery Association and issued in May 2008.

Preface

Summary

The IRSA® (International RadioSurgery Association) Radiosurgery Practice Guideline Initiative aims to improve outcomes for brain metastases radiosurgery by assisting physicians and clinicians in applying research evidence to clinical decisions while promoting the responsible use of health care resources.

Copyright

This guideline is copyrighted by IRSA (2008) and may not be reproduced without the written permission of IRSA. IRSA reserves the right to revoke copyright authorization at any time without reason.

Disclaimer

This guideline is not intended as a substitute for professional medical advice and does not address specific treatments or conditions for any patient. Those consulting this guideline are to seek qualified consultation utilizing information specific to their medical situation. Further, IRSA does not warrant any instrument or equipment nor make any representations concerning its fitness for use in any particular instance nor any other warranties whatsoever.

KEY WORDS • brain metastases • WBRT • stereotactic radiosurgery • Gamma Knife® • linear accelerator
• Bragg peak proton therapy • irradiation

Consensus Statement

Objective

To develop a consensus-based radiosurgery practice guideline for brain metastases treatment recommendations to be used by medical and public health professionals who diagnose and manage patients with brain metastatic disease.

Participants

The working group included physicians and physicists from the staff of major medical centers that provide radiosurgery.

Evidence

The first author (AN) conducted a literature search in conjunction with the preparation of this document and development of other clinical guidelines. The literature identified was reviewed and opinions were sought from experts in the diagnosis and management of brain metastases including members of the working group.

Consensus Process

The initial draft of the consensus statement was a synthesis of research information obtained in the evidence gathering process. Members of the working group provided formal written comments that were incorporated into the preliminary draft of the statement. No significant disagreements existed.

The final statement incorporates extensive relevant evidence obtained by the literature search in conjunction with the final consensus recommendations supported by all working group members.

Group Composition

The radiosurgery guidelines group is comprised of neurosurgeons, neuro-oncologists, radiation and medical oncologists and physicists. Community representatives did not participate in the development of this guideline.

Names of Group Members: Ajay Niranjana, M.B.B.S., M.Ch., Neurosurgeon, Chair; L. Dade Lunsford, M.D., Neurosurgeon; Richard L. Weiner, M.D., Neurosurgeon; Gail L. Rosseau, M.D., Neurosurgeon; Gene H. Barnett, M.D., F.A.C.S., Neurosurgeon; Massaki Yamamoto, M.D., Neurosurgeon; Lawrence S. Chin, M.D., F.A.C.S., Neurosurgeon; Paul J. Miller, M.D., Radiation Oncologist; Andrew E. Sloan, M.D., Neurosurgeon; Burton L. Speiser, M.D., Radiation Oncologist; Sandra S. Vermeulen, M.D., Radiation Oncologist; Harish Thakrar, M.D., Radiation Oncologist; Frank Lieberman, M.D., Neuro-Oncologist; David Schiff, M.D., Neuro-Oncologist; Sammie R. Coy, Ph.D., Medical Physicist; Tonya K. Ledbetter, M.S., M.F.S., Editor; Rebecca L. Emerick, M.S., M.B.A., C.P.A., ex officio.

Conclusions

Specific recommendations are made regarding target population, treatment alternatives, interventions and practices and additional research needs. Appropriate use of radiosurgery for patients with brain metastases is recommended.

This guideline is intended to provide the scientific foundation and initial framework for patients who have been diagnosed with brain metastases. The assessment and recommendations provided herein represent the best professional judgment of the working group at this time, based on clinical research data and expertise currently available. The conclusions and recommendations will be regularly reassessed as new information becomes available.

Stereotactic Radiosurgery

Brain stereotactic radiosurgery (SRS) involves the use of precisely directed, closed skull, single session radiation to create a desired radiobiologic response within the brain target with acceptable minimal effects on surrounding structures or tissues. In the case of brain metastases, highly conformal, precisely focused radiation is delivered to the metastatic tumor in a single session under the direct supervision of a radiosurgery team. At Centers of Excellence, the radiosurgery team includes a neurosurgeon, a radiation oncologist, a physicist and a registered nurse.

Overview of Brain Metastases

Epidemiologic Features

Metastatic brain tumors are the most common intracranial neoplasms in adults and are a significant cause of morbidity and mortality. They outnumber primary brain tumors by a ratio of 10:1.¹⁰⁷ Approximately 1.37 million individuals were diagnosed with cancer in 2005–2006. Conservative estimates suggest that 100,000–170,000 new cases of brain metastases are diagnosed every year in the United States (U.S.).^{59,108} Between 20% and 40% of all patients with metastatic cancer will have brain metastases at autopsy.¹⁰⁶ The estimate of the incidence rate of metastatic brain tumors varies from 8.3–11 per 100,000.^{91,127} In two large population cohorts of patients who were diagnosed with colorectal, lung, breast or kidney carcinoma or melanoma, brain metastases were diagnosed in 8.5–9.6% of patients.^{6,108} The incidence varied by primary tumor site. The cumulative incidence was estimated at 16.3–19.9% in patients with lung carcinoma, 6.5–9.8% in patients with renal carcinoma, 6.9–7.4% in patients with melanoma, 5.0–5.1% in patients with breast carcinoma, and 1.2–1.8% in patients with colorectal carcinoma.

The majority of patients who develop brain metastases have a known primary cancer (metachronous presentation). No primary systemic site of cancer is detected in 5–10% of patients with brain metastases.^{58,95} Patients with a history of lung cancer have the shortest latency period between the time of initial diagnosis and the diagnosis of brain metastases (median, 6–9 months). For renal cell carcinoma, the interval is approximately one year. Patients with breast, melanoma

and colon cancer experience spread of their disease to the brain at a median latency of approximately two years.¹⁰⁶ The rate of breast cancer metastases to the brain may be higher among patients treated with trastuzumab (Herceptin®).⁷ This may be due to the preference for the brain by HER-2-positive tumor cells, poor penetration of the CNS by the drug or improved extracranial control resulting in improved survival and late tumor spread to the CNS.⁷

The detection rate of brain metastases appears to be increasing. This increase has been variably attributed to improvements in systemic therapy leading to longer survival, an aging patient population, and the ability of magnetic resonance imaging (MRI) to detect small metastases.¹³⁰ The majority of brain metastases are multiple, although the reported percentage of patients with solitary or multiple lesions may vary with the imaging modality used to make the diagnosis. In the CT (computed tomography) era 50% of lesions were thought to be solitary at the time of neurologic diagnosis.⁸⁸ In an analysis of the Radiation Therapy Oncology Group (RTOG) database of brain metastases patients, 19% of patients presented with a single brain metastasis on MRI, and 50% of patients had 1–3 brain metastases. Melanoma has the greatest tendency to produce multiple lesions (75% of patients). Multiple lesions are also frequent in metastases from colon, breast and lung cancer. Renal cell metastases are more likely to be single.²⁷

Sex

Predilection for gender follows that of the primary tumor. Lung cancer is the most common source of metastases in male patients, while breast cancer is the most common source in female patients. As the frequency of lung cancer in women increases, it may become the most common primary tumor to metastasize to the brain in women as well.

Age

Incidence of brain metastases based on age parallels that of primary systemic tumors. Brain metastases are most common in the fifth to seventh decades of life. Sarcomas and germ cell tumors are the most common solid tumors to metastasize to the brain in children.⁴⁵

Pathophysiology

Metastatic spread to the brain through blood circulation occurs primarily via arterial circulation and less often via the Batson venous plexus (pelvic and GI tumors).¹²⁹ Arterial blood must pass through the lungs before entering the brain and larger clumps of tumor cells are filtered out in lung capillaries. Many emboli traveling to the brain via the arterial route originate either from a primary lung tumor or a metastatic site in the lung; however, single tumor cells may pass through the capillaries of the lung. The metastatic cells then get trapped in gray-white junction or watershed areas, because of the change in the size of the blood vessels in these areas.²⁸ Less than 0.1% of deposited cells ultimately form metastatic tumors.¹⁴ Once the metastatic tumor embolus reaches 1 mm in size, tumor-induced angiogenesis increases vascular permeability and disrupts the blood-brain barrier (BBB).¹⁴ New capillary endothelial cells in metastatic brain

tumors display morphological and functional characteristics associated with the blood vessels of the primary cancer.⁶⁵

Macroscopic Findings

Intracranial metastases can be categorized by location as skull, dura, leptomeninges and parenchymal brain metastases. Lesions of the brain and leptomeninges account for 80% of intracranial metastases. The majority of brain metastases (approximately 80%) are located in the cerebral hemispheres. The cerebellum (10–15%) and brainstem (2–3%) are less frequently involved.⁸⁷ Most metastases are round, well-demarcated lesions located at the junction of gray and white matter. Metastatic lesions in the brain displace surrounding brain parenchyma as they grow. Some metastases have a miliary type of distribution throughout the parenchyma. Leaky tumor vessels result in an extensive zone of edema surrounding the tumor. Cystic degeneration, necrosis and areas of hemorrhage are often seen. Specific tumors may have a more characteristic gross appearance. The metastatic lesions of melanoma, choriocarcinoma and renal cell carcinoma often develop intratumoral hemorrhages.⁸⁴ Edema of the adjacent brain parenchyma is often prominent and sometimes disproportionate to the small size of the lesions.²⁹ Meningeal carcinomatosis may occur in patients with lung and breast carcinoma, malignant melanoma, and less commonly, with lymphoma, leukemia and other tumors.

Histopathologic Features

The histopathologic features of metastatic lesions are usually similar to those of the primary tumor from which they originate. Although the majority of metastatic lesions may appear clearly demarcated from adjacent brain on both gross and microscopic examination, microinvasion of tumor cells is invariably present. This aspect is particularly evident in metastases of small cell lung carcinomas (SCLC) and melanomas. Brain metastases elicit a number of reactions from the brain parenchyma. Reactive astrocytosis is often present surrounding the metastatic nodules. Vascular proliferation with variable degrees of endothelial proliferation may be seen within and surrounding the tumor masses. This rich neovasculature appears to play a significant role in development and maintenance of the metastatic lesions, and is a major contributory factor to the vasogenic edema that accompanies brain metastases.¹⁰⁶ Necrosis is frequent and macrophage infiltration may be prominent around areas of necrosis.

For a newly diagnosed brain metastasis of unknown origin, adjunctive morphological techniques such as immunohistochemistry are valuable and can guide the search for a primary site.²⁹ Immunohistochemistry, in conjunction with the clinical history, can define specific cell lineages in the great majority of cases. In cases in which light microscopy and immunohistochemistry are inconclusive, electron microscopy is a useful adjunctive tool to study subcellular structures that may be diagnostic of cellular lineage. Molecular genetic analysis is the latest resource for the complete evaluation of metastatic tumors of unknown origin.

Clinical Presentation

Approximately two-thirds of brain metastases eventually become symptomatic. The clinical presentation of brain metastases is similar to any intracranial mass lesion. Presenting signs and symptoms of an intracranial mass include headache (70%), seizures (30–60%), cognitive impairment (30%), papilledema (8%), miscellaneous focal neurological deficits and intracranial hemorrhage, among others.^{95,106} Patients may develop obstructive hydrocephalus, particularly those with lesions in proximity to crucial areas of narrow cerebrospinal fluid (CSF) flow such as the 3rd or 4th ventricle or the foramen of Monro. Symptoms typically have a gradual onset but 5–10% of patients present with sudden onset of focal neurological symptoms^{71,97} associated with intratumoral hemorrhage, particularly from metastases originating from melanoma, choriocarcinoma or renal cell carcinoma.¹¹⁹ Even though a relatively small percentage of lung metastases manifest with hemorrhage, these lesions represent the most common source of hemorrhage because of their much greater overall occurrence. Seizures are common on initial presentation and are the first sign of a brain metastasis in approximately 10–20% of patients.⁶¹ Tumors that cause seizures are frequently located in the cerebral hemispheres and often involve the cerebral cortex. Up to one-third of patients presenting with brain metastases do not have a prior diagnosis of cancer.⁷⁷ When a patient without a history of systemic cancer presents with new neurological findings and a brain mass is discovered on CT or MRI, a plain chest radiograph and chest CT are always recommended because the majority of tumors that metastasize to the brain are from lung primaries.¹⁰⁶ Computed tomography of the abdomen and pelvis occasionally reveals an unknown primary cancer but may also offer evaluation of the systemic disease burden by imaging the liver, adrenals and lymph nodes. Further search for a primary cancer is rarely productive without positive features in the patient's history or localizing signs on physical examination that suggest a primary tumor.¹²³ Despite extensive evaluations, at least 15% of patients with brain metastases may remain without a definite primary cancer site.⁷⁷ For these patients stereotactic biopsy or excision of brain neoplasm is recommended to determine the final treatment strategy.

Imaging

Most patients with a known primary tumor undergo imaging studies when neurologic signs and symptoms develop. Contrast-enhanced CT is used widely because of its easy accessibility and low cost. On noncontrast CT, metastatic lesions may be of a density less than, equal to, or greater than adjacent brain parenchyma. Hyperdensity in a metastasis on noncontrast CT is more likely to be hemorrhage than calcification. Administration of IV contrast (30–40 g iodine) increases the diagnostic accuracy of CT. Most metastases enhance after a standard dose of IV contrast. Use of a higher dose of contrast (80–85 g iodine) and scanning delayed 1–3 hours after injection of the contrast agent offers a further increase in the detection of multiple metastases, and is appropriate if MRI is not available. Contrast-enhanced CT can detect major leptomeningeal spread. Studies

comparing contrast-enhanced CT with contrast-enhanced MRI indicate that approximately 20% of patients who demonstrate a single lesion on CT may demonstrate multiple lesions on MRI.

MRI with contrast enhancement currently is the procedure of choice, since MRI is more sensitive and specific than other imaging techniques in determining the presence, location and number of metastases.⁵⁰ On MR multiple lesions with marked vasogenic edema and mass effect are typically seen in patients with brain metastases. Lesions are isointense to mildly hypointense on T1-weighted images and hyperintense on T2-weighted images or fluid attenuation inversion recovery images. Surrounding edema is relatively hyperintense on fluid attenuation inversion recovery T2-weighted images and hypointense on T1-weighted images. A metastasis itself may have various signal intensities depending on the types of tissue present within the lesion (e.g., blood products, necrosis and melanin). The appearance of blood products on T1-weighted images depends on the “age” of bleeding, and ranges from isointense in the first 24 hours to hyperintense after 24–72 hours. Melanin is paramagnetic and hyperintense on T1 and hypointense on T2-weighted images. Metastatic melanomas often have both components (blood and melanin), which appear bright on noncontrast T1-weighted scans. T2-weighted images are used to estimate the extent of peritumoral edema. Following contrast administration, solid, nodular or irregular ring patterns of enhancement are seen. Contrast-enhanced MRI is the best method for detection of meningeal tumor seeding. Carcinomatous meningitis is usually seen as an irregular brightly enhancing pial surface on T1-weighted imaging with contrast. The arachnoidal surfaces, ventricular ependyma or dura may enhance pathologically as well. The usefulness of diffusion-weighted and perfusion-weighted imaging and proton-MR spectroscopy in the initial diagnosis of brain metastases has not been established. Gadolinium-enhanced MRI detects smaller lesions, and provides better soft-tissue contrast, relatively stronger enhancement with paramagnetic contrast agents, images that lack bone artifacts and direct multiplanar imaging. High-dose gadoteridol (ProHance[®]) detects additional smaller lesions compared with routine-dose gadopentetate dimeglumine (Magnevist[®]). Magnetization transfer used with routine-dose gadolinium contrast is closely comparable to the high-dose technique. For patients with multiple brain metastases, gradient recalled acquisition using double-dose contrast and 2 mm thick slices is a reliable method to detect brain metastases.³²

The interpretation of subsequent radiological studies in patients who have undergone a complete surgical resection of their tumors is fairly straightforward, as any new enhancement in the lesion site can be considered local recurrence. This is not always the case after radiosurgery, in which recurrent or residual tumor must be differentiated from radiation necrosis. Radiation necrosis and recurrent brain tumor can manifest with similar symptoms and may be indistinguishable on MRI. Fluorodeoxyglucose-positron emission tomography (FDG-PET) has been proposed as a diagnostic alternative, particularly when coregistered with MRI. For brain metastases with MRI coregistration, FDG-

PET has a sensitivity of 86% and specificity of 80%.¹⁹ There are few preliminary reports on the utilization of MR spectroscopy to distinguish between radiation necrosis and recurrent brain metastasis.^{40,102}

Management Options

Metastatic brain tumors require multimodal management including drugs, surgery, radiosurgery, radiation therapy, chemotherapy, gene therapy and other innovative approaches.^{18,78,100,103,114,133}

Symptomatic Medical Management

The initial drug of choice for treating cerebral edema associated with a brain metastasis is a corticosteroid (dexamethasone or methylprednisolone). The benefit of corticosteroids is often dramatic and may be evident within hours, but ultimately they are insufficient unless definitive tumor management is pursued. Control of vasogenic cerebral edema and removal of the offending mass can result in improved control of the seizure disorder. For prophylaxis and maintenance therapy, phenytoin is the most frequently prescribed agent. There has been a trend away from phenytoin toward levetiracetam, because of decreased rash, no need for lab monitoring and no induction of CYP3A4. Carbamazepine, phenobarbital, valproic acid and levetiracetam are often added for breakthrough seizures or to replace phenytoin if toxicity or allergic reactions occur. Benzodiazepines are used for patients in status epilepticus (continuous seizure activity lasting longer than 30 minutes). Although there is agreement that patients who present with seizures require antiepileptic drug therapy, the situation is not as clear for prophylactic anticonvulsants for brain metastases. In a meta-analysis of 12 studies in patients with brain tumors of all etiologies (including brain metastases), prophylactic anticonvulsants did not protect against subsequent seizures.⁴⁴ The American Academy of Neurology has published a position paper against the use of prophylactic anticonvulsants.⁴⁴

Tumor Resection

Some prospective studies have demonstrated that, in appropriately selected cases, surgical treatment can effectively prolong survival in patients with one or rarely more than one brain metastasis. Not all patients will benefit from surgical resection. The location and accessibility of the tumor is a crucial factor in surgical decision making.

Surgery for Single Brain Metastasis

Patients experiencing significant, medically refractory symptoms related to volume and mass effect may require craniotomy for tumor removal, regardless of the status of their extracranial disease. However, patients with small cell lung carcinomas, germ cell tumors, and primary or secondary CNS lymphomas may not need surgical resection despite being symptomatic because these lesions generally respond dramatically to radiosurgery, fractionated radiotherapy or systemic chemotherapy, leading to very rapid resolution of symptoms. Patients whose symptoms cannot be palliated successfully with medical management (including high dose steroids) and whose lesions can be excised without significant

risk of producing or worsening a neurologic deficit are potential candidates for craniotomy.

In the case of a single, asymptomatic brain metastasis from an undiagnosed primary site, the decision for surgery becomes more complex. For most patients obtaining a tissue diagnosis is mandatory. If a potential extracranial source is identified, then biopsy of such a lesion is often performed before the intracranial disease is addressed. For patients in whom a “nonsurgical” tumor type such as small cell lung carcinoma is diagnosed by biopsy, a potentially unnecessary craniotomy can be avoided. In other cases, knowledge of the putative histologic features of the single brain metastasis may lead to a recommendation for whole-brain radiation therapy (WBRT) and/or SRS rather than craniotomy for tumor removal.

Stereotactic biopsy of a solitary metastasis in unresectable locations is indicated to obtain a tissue diagnosis in patients when no other source has been identified that can be biopsied more safely. Biopsy is also indicated when the chance of a coincidental nonmalignant intracranial lesion is greater than the probability of a significant biopsy-related complication. In most series the rate of such complications approximates 1%. Many specialists also strongly consider a stereotactic biopsy in patients whose primary and systemic malignant disease has been in remission for a length of time sufficient to raise the question of a new malignancy rather than a metastasis. Stereotactic or open biopsy of a single brain metastasis may also be indicated after treatment to distinguish between recurrence and treatment effects such as radiation necrosis.

Several retrospective series report benefits of surgery in selected cases of single brain metastases from lung,⁶⁷ breast, colon^{36,47,131} and renal cell origins.^{48,116,132} The potential benefit of resection to long-term survival is significantly influenced by the presence of extracranial metastases.^{25,122} Surgery for brain metastases from esophageal, gastric, pancreatic and hepatocellular primary sites is rarely recommended due to poor overall survival.¹³⁵ Craniotomy may be indicated in patients whose lesions have progressed after radiosurgery and/or fractionated radiation and proven unresponsive to systemic chemotherapy.

Single choriocarcinoma metastases to brain are usually detected after childbirth and are generally very sensitive to radiation and/or systemic chemotherapy. Occurrence during pregnancy or lesions unresponsive to systemic therapy or radiotherapy may mandate resection of a solitary choriocarcinoma metastasis to the brain.⁶⁸ Germ cell tumors, particularly those of testicular primary origin, are often very sensitive to radiosurgery or WBRT and systemic chemotherapy. Thus, even relatively large lesions may be successfully managed without craniotomy. Progressive symptoms in the face of medical management or presentation in extremis may, however, demand surgical resection.

Three randomized trials of craniotomy followed by WBRT versus WBRT alone for single brain metastases have been conducted. Two demonstrate that surgery prolongs high-quality survival,^{90,125} and one does not.⁷⁹ Resection of single metastases may be indicated for symptomatic lesions or in the hope of providing quick relief from pressure effect.

Table 1: Randomized Trials of Resection Followed by WBRT Versus WBRT Alone

First Author	Management Modalities	Patient Number	Patient Eligibility	Median Survival (Months)	Statistical Significance
Patchell 1990 ⁹⁰	WBRT	23	Age ≥ 18 KPS ^a ≤ 70	3.5	p < 0.01
	WBRT + Resection	25		9.2	
Vecht 1993 ¹²⁵	WBRT	31	Age ≥ 18 WHO PS ^b ≥ 2	6	p = 0.04
	WBRT + Resection	32		10	
Mintz 1996 ⁷⁹	WBRT	43	Age ≥ 50 KPS < 80	6.3	p = 0.24
	WBRT + Resection	41		5.6	

^a Karnofsky Performance Status

^b World Health Organization Performance Status

Surgery for Multiple Metastases

Traditionally, multiple brain metastases were considered a contraindication to surgical intervention and were treated exclusively with WBRT.^{87,99} Resection of multiple metastases was undertaken only in the case of life-threatening lesions or in cases in which the diagnosis was in question.⁸⁶ There are few recent reports recommending surgical resection of multiple brain metastases in properly selected patients.^{11,52}

Whole-Brain Radiation Therapy

Whole-brain radiation therapy has been a widely applied management for patients with brain metastases. Various dose and fractionation schedules have been tested in earlier clinical trials but no single schedule was proven superior in terms of overall survival. Concern about potential late neurotoxicity with WBRT and the development of radiosurgery have led to the introduction of newer approaches which do not favor upfront WBRT for all patients. In recent years clinical research has attempted to identify various management strategies appropriate for patients with metastatic brain cancers.

Studies Investigating Dose and Fractionation Schedules of WBRT

To investigate the effects of WBRT on brain metastases the RTOG conducted several studies using various dose and fractionation schedules.^{12,57,81} Borgelt et al. reported the outcome of various dose and fractionation schedules used in RTOG 69-01 and 73-61.¹² Doses ranging from 30–40 Gy in 6–20 fractions (30 Gy in 6 fractions, 40 Gy in 20 fractions) were tested. Although there was no survival difference, the median time to neurologic progression was longer when more protracted schedules were used. No survival difference was seen when patients were randomized to 30 Gy in 10 fractions versus 30 Gy in 6 fractions in RTOG 79-16.⁵⁵ One-third of patients died of brain disease suggesting the need for further improvement in CNS control (but also emphasizing that studies that use survival as an endpoint in brain metastases trials will have difficulty remaining relevant since most death is non-neurologic). No single WBRT dose schedule has been proven superior for overall survival because most patients died of systemic disease. Gaspar et al. performed a recursive partitioning analysis (RPA) on patients enrolled for WBRT in RTOG trials from 1979 to 1993.⁴¹ The median survival was 7.1 months for RPA class I (controlled primary tumor, age \leq 65 years, Karnofsky Performance Status (KPS) \geq 70, and absence of non-CNS metastases). The median survival was 2.4 months for RPA class III (KPS $<$ 70, age $>$ 65, and presence of other systemic disease). Other patients (RPA class II) had an intermediate median survival of 4.2 months. The RTOG 85-28 trial evaluated higher doses of radiation (twice per day with accelerated hyperfractionation) in patients who had a single brain metastasis.³³ A total radiation dose of 32 Gy was delivered at 1.6 Gy per fraction which was given twice a day. In addition patients received focal radiation boosts to total doses of 48 Gy, 54.4 Gy, 64 Gy and 70.4 Gy. Patients treated to 54.4 Gy or higher showed improved survival and better neurologic function. When this regimen (54.4 Gy) was compared with 30 Gy in 10 fractions, no benefit to overall survival with the accelerated hyperfractionated regimen was noted.⁸¹ The toxicity was similar in both arms.

Several randomized trials have studied the effect of radiation sensitizers on local tumor control in patients receiving WBRT. Bromodeoxyuridine (BrdUrd) was evaluated in RTOG 89-05 in patients with brain metastases.⁹³ Patients were randomized to 37.5 Gy in 15 fractions WBRT versus WBRT plus BrdUrd (0.8 g/m² four days per week during WBRT). No survival difference was noted. In another study patients were randomized to WBRT (30 Gy in 10 fractions) or WBRT plus motexafin gadolinium (MGd).⁷⁵ Motexafin gadolinium selectively targets tumor cells where it generates reactive oxygen species. Motexafin gadolinium improved the time to neurologic progression and neurocognitive function in the subset of lung cancer patients, but had no effect on overall survival. A follow-up trial with this agent was restricted to non-small cell lung cancer (NSCLC) patients. This randomized, controlled Phase 3 trial, known as the SMART (Study of Neurologic Progression with Motexafin Gadolinium And Radiation Therapy) trial was designed to compare the safety and efficacy of WBRT alone to WBRT plus MGd. The primary endpoint of the study was time to neurologic progression (TNP). The trial enrolled 554 patients from 94 centers in North America, Europe and Australia. Although patients receiving MGd had a longer time to neurologic progression, the study's primary endpoint, the difference compared with patients in the control arm, did not reach statistical significance.⁷⁴ Another phase III study tested RSR13 (efaproxiral) in combination with WBRT. RSR13 binds to hemoglobin and reduces its affinity for oxygen thus increasing tissue pO₂. In this study of WBRT plus supplemental oxygen with or without RSR13, overall survival increased from 4.6 months to 8.7 months in the subset of breast cancer patients. The role of RSR13 is currently being evaluated for patients with brain metastases from breast cancer.¹¹⁰

The combined effect of temozolomide and WBRT has also been studied. In a phase III trial Antonadou et al. randomized patients to WBRT alone versus WBRT plus temozolomide (75 mg/m² daily during WBRT).³ These investigators reported significantly improved radiographic response rates in patients treated with WBRT and temozolomide compared with WBRT alone (96% vs. 67%). In addition, patients treated with combined therapies had greater neurological improvements and lower requirements for corticosteroids. In another randomized study Verger et al. reported similar results.¹²⁶ The addition of temozolomide to WBRT did not affect overall survival; however, patients treated with combined therapies had better 90-day progression-free survival and a lower rate of death secondary to neurological causes. Although there was a trend toward a modest benefit in median survival, no significant improvement in survival was documented.

WBRT as an Adjuvant to Surgical Resection

Patchell et al. evaluated the role of WBRT in addition to surgical resection in a prospective randomized study. Postoperative MRI was used to document that resection was complete and no other brain metastases were present.⁸⁹ Patients who had complete resection of single brain metastases were randomized to adjuvant WBRT (50.4 Gy at 1.8 Gy per fraction) or observation. The crude risk of local

recurrence with surgery alone was 46%, and the actuarial risk of local recurrence at one year was 70%. The results showed that WBRT reduced the incidence of recurrence of brain tumors anywhere in the brain from 70% in the surgery alone group to 18% in the adjuvant WBRT group. Whole-brain radiation therapy reduced the incidence of local failure at the primary resection site and reduced the incidence of new brain tumors elsewhere in the brain. The WBRT group had a reduced risk of neurologic death. The overall survival in both arms was not different, although the study was not statistically powered to detect that endpoint. No difference was seen in functional independence as measured by KPS. Although this study demonstrated a benefit in terms of reduction in brain recurrence, it can be argued that because no overall survival benefit was seen, WBRT can be delayed. Although WBRT would reduce intracranial relapse after surgery or radiosurgery, the toxicity of this therapy has been a concern. DeAngelis et al. reported 12 patients who were cured from brain metastases but developed dementia and severe disability.²⁶ Eight of the twelve patients were also treated with surgery. All patients who experienced neurologic morbidity received a high dose per fraction (3–6 Gy), whereas no patients treated with lower daily doses had this complication. The studies with a lower dose per fraction or lower total dose seemed to have a much lower risk of toxicity, although many of these studies did not use sensitive instruments to assess neurocognitive function. Although WBRT reduces the incidence of progression of disease in the brain following surgery or radiosurgery, and has been shown in prospective randomized trials to improve quality of life, the role of adjuvant WBRT remains controversial in patients with oligometastatic disease since it does not clearly translate into a survival advantage. On the other hand there are tumors such as SCLC that tend to seed in a miliary fashion and are controllable with low doses of WBRT, suggesting a role for “prophylactic” WBRT.

Radiosurgery

Stereotactic radiosurgery is a surgical technique that employs highly focused radiation to treat intracranial targets with submillimeter precision in a single session. Stereotactic radiosurgery offers many of the benefits of craniotomy without its risks. Stereotactic radiosurgery does not cause the physiological stress of an open operation and can be performed in an outpatient setting. In the same session, SRS may be used to treat multiple lesions in widely disparate locations and in eloquent locations not conducive to open surgical approaches. Three types of devices are commonly used for radiosurgery: the multisource cobalt⁶⁰ unit known as the Gamma Knife,[®] specially modified or dedicated linear accelerators like Novalis Tx[™] and Axesse,[™] or charged-particle irradiators. The Leksell Gamma Knife[®] consists of 192 (Leksell Gamma Knife[®] Perfexion[™]) or 201 (Models U, B, C and 4-C) cobalt⁶⁰ sources that emit gamma irradiation. The epicenter of delivery of each dose (or “shot”) of radiation is always in the center of the sphere defined by the helmet. The Leksell Gamma Knife[®] is the only technology designed for brain tumors to provide the higher level of accuracy necessary in the brain. Stereotactic radiosurgery allows delivery of radiation to only a small volume with a rapid dose fall-off.

The second method for delivering SRS is by irradiation produced by modified or dedicated linear accelerator (Novalis Tx[™] and Axesse[™]), a machine that generates high-energy photons. Linear accelerators can be used for SRS by focusing the beams through a variety of fixed, shaped fields at the target, or by a variety of arcs at the axis of rotation. Linear accelerator technology is made to target within the whole body and may not provide the same accuracy within the brain as the cobalt⁶⁰ based technology. Proton beam systems use fixed high-energy beams that are either crossfired (non-Bragg peak) or use Bragg peak effect to deposit radiation in the tumor.

Radiosurgery as the sole initial management or as a boost before or after WBRT has emerged as a widely practiced treatment modality for brain metastases. The goal of radiosurgery without WBRT is to achieve brain control without the possible long term neurotoxic or cognitive side effects of WBRT.¹⁷ The rationale for radiosurgery, when used as a boost after WBRT, is to achieve improved local brain tumor control. Radiosurgery boost improves survival in selected patients in whom the predominant problem is brain disease rather than extracranial disease. Radiosurgery is also used as salvage treatment for progressive intracranial disease after surgery or WBRT. Traditionally radio-insensitive histologies tend to be more responsive to SRS than to conventional fractionated radiation treatment. In addition, SRS causes indirect vascular injury and subsequent sclerosis of blood vessels, and eventual compromise of the blood supply and circulation within the tumor.¹²¹ The overall side effects of SRS are limited but can occasionally be serious. There are very few acute side effects of SRS related to the radiation. Stereotactic radiosurgery may cause mild fatigue and sometimes a temporary patch of hair loss if the tumor is close to the skull and scalp. There is a risk of late side effects that can develop, the most common and serious of which is tumor radionecrosis.¹³⁴ Radiation necrosis is damage to the tumor and or adjacent brain in the high-dose area. This can result in edema and additional side effects produced by the mass including seizures and neurological deficits. Radionecrosis can often be managed with corticosteroids. Occasionally surgical intervention is required to reduce the mass effect. The risk of symptomatic radionecrosis is usually less than 5%.^{2,5,56} A multicenter phase I/RTOG trial involving SRS documented safe SRS in patients previously treated with standard external beam radiation therapy.¹¹¹ Early publications showed good control rates and led to further investigation.^{24,64,76,120} Retrospective series have consistently revealed local control of the target lesions in the range of 80–85% or even higher with a very acceptable side effect profile.^{5,10,20,30,37,51,70} Prospective randomized trials have demonstrated that the one-year local control rate of target lesions with radiosurgery is 73%, which increases to 82–89% with the addition of WBRT.^{2,4}

Retrospective Studies for SRS

Patients treated with conventional open surgical resection without WBRT had a 46% risk of failure at the site of the resection in a randomized trial evaluating the role of WBRT after surgical resection.⁸⁹ In subsequent studies patients were treated with SRS alone (without WBRT). These studies

found excellent local control (70–80% at one year).^{21,83} Other published series of patients treated with SRS have demonstrated a risk of distant brain failure at one year, ranging from 43% to 57%.^{22,49,66,117} In general, the risk of new metastasis in patients with solitary tumors is approximately 37% (crude), but the actuarial risk is 50% at one year.^{62,89} The histologic features or tumor type may play a role, with melanoma being more likely to be associated with multiple metastases than some other tumor types.⁹⁵ Despite a relatively high risk of new metastases outside the radiosurgery volume in patients who have SRS alone, retrospective studies have not confirmed a survival benefit to adjuvant WBRT.^{94,117,118} Freedom from local progression in the brain at one year was significantly superior in patients who received both SRS and WBRT compared with SRS alone (28% vs. 69%), although the overall survival rate was not significantly different.⁴⁹ A retrospective, multi-institutional study in which patients were treated with SRS alone (n = 268) or SRS + WBRT (n = 301) also reported no significant difference in the overall survival rate.¹⁶¹ Despite the higher rate of new lesions developing in patients treated with SRS alone, the overall survival appears to be equivalent to SRS + WBRT since salvage therapies are fairly effective and patients' extracranial disease is frequently the cause of death.¹¹⁷ Only 24% of patients managed initially with radiosurgery alone required salvage WBRT. Pirzkall et al. reported that there was no survival benefit for an overall group of 236 patients with adjuvant WBRT but these authors noted a trend toward improved survival in a subset of patients with no extracranial tumor (15.4 vs. 8.3 months, p = 0.08).⁹⁴

Chidel et al. reported on 78 patients managed initially with SRS alone and 57 patients treated with SRS and adjuvant WBRT.¹⁵⁷ Whole-brain radiation therapy did not improve the overall survival rate but was useful in preventing both the local progression and the development of new brain metastases (74% vs. 48%, p = 0.06). These retrospective studies suggest that WBRT will improve local and distant control in the brain, but do not clearly demonstrate a survival advantage.¹¹⁷

A multicenter retrospective analysis was performed with 502 patients treated at 10 institutions in which all of the patients were treated with WBRT and SRS. The patients were stratified by the recursive partitioning analysis and compared with similar patients from the RTOG database who had been treated with WBRT alone.¹⁰⁴ The study revealed that patients with higher KPS, controlled primary tumor, absence of extracranial metastases and lower RPA class had statistically superior survival. The addition of an SRS boost resulted in a median survival of 16.1, 10.3 and 8.7 months, respectively, for RPA classes I, II and III. This is in comparison to 7.1, 4.2 and 2.3 months for similar RPA class patients from the RTOG database. This improvement in overall survival, stratified by RPA class with an SRS boost, was statistically significant.¹⁰⁴ In a recent study SRS alone was found to be as effective as resection plus WBRT in the treatment of one or two brain metastases for patients in RPA classes I and II.⁹⁸

Table 2: Selected Recent Retrospective Studies of Radiosurgery for Brain Metastases

First Author	Year	No. of Patients	Primary Organ	Median Survival (Months)	Median Margin Dose (GY)	Local Control
Gaudy-Marqueste ⁴²	2006	106	Melanoma	5.09	25	84%
Bhatnagar ⁹	2006	205	Mixed	8	16	71% at 1 yr
Chang ¹⁶	2005	109	NSCLC	7.5	18	64% renal 47% melanoma
Serisawa ¹⁰⁹	2005	521	Mixed	9	20	95.70%
Nam ⁸²	2005	130	Mixed	8.75	17.9	63.90%
Pan ⁸⁵	2005	191	all lung	14	18	91%
Gerosa ⁴³	2005	504	all NSCLC	14.5	21.4	95%
Lippitz ⁶³	2004	215	Mixed	7.8–13.7	22	93.90%
Hasegawa ⁴⁹	2003	121	Mixed	8	18.5	79%
Petrovich ⁹²	2002	458	Mixed	9	18	87%
Sheehan ¹¹²	2002	273	all NSCLC	7	16	86%
Amendola ¹	2000	68	all breast	7.8	15–24	94%
Simonova ¹¹⁵	2000	237	Mixed	6–12	21.5	95%

Radiosurgery Versus Resection for Single Brain Metastases

The available data indicate that SRS and open surgical resection (where feasible) are both excellent treatment options for patients with solitary brain metastases. Tumor resection offers immediate relief of symptoms in patients with a large symptomatic tumor causing mass effect. Stereotactic radiosurgery has a number of advantages in comparison to open surgical resection. Stereotactic radiosurgery does not require open resection and can be performed as an outpatient procedure. Compared with open surgical resection SRS is a more cost-effective procedure,⁷³ and can be performed for any tumor location. Several investigators have discussed the need to evaluate the outcome of SRS and open surgical resection in a prospective fashion.^{5,80} However, it is unlikely that such a study will ever be performed due to the large number of patients required and very difficult randomization, because of current outcome data, widely variant risks and eligibility for resection. The prospective trial by the University of Kentucky demonstrated a 48% local control rate with surgery alone⁹⁰ whereas the prospective trial by Aoyama demonstrated a local control rate of 73% with SRS alone.⁴ However no difference in survival has ever been demonstrated.⁵

Role of SRS for Multiple Brain Metastases

Stereotactic radiosurgery is an effective treatment for patients with multiple brain metastases. A substantial amount of

published literature now supports use of radiosurgery in the treatment of multiple brain metastases. Stereotactic radiosurgery offers a very high control rate with a low risk of serious side effects. The RTOG 95-08 study authors concluded that addition of stereotactic radiosurgery to WBRT improved functional autonomy for all patients; therefore WBRT and stereotactic radiosurgery should be considered for patients with two or three brain metastases. For patients with good performance status up to three brain metastases, SRS in addition to WBRT is reasonable.

Role of Radiosurgery and Resection for Multiple Brain Metastases

The role of surgery and SRS may be complementary for patients with multiple metastases, particularly in cases where the largest lesion causes symptoms of mass effect and small lesions are unresectable because of their small size or deep location. In this context, the ideal treatment may be surgical resection of the larger or more symptomatic lesions combined with SRS for the surgically inaccessible lesions. This combination approach allows for local treatment of all the brain lesions, which may be the critical factor for a successful outcome.¹¹ Since the University of Kentucky study clearly demonstrated the need for adjuvant therapy after resection of a brain metastasis, WBRT is required for these patients. Alternatively, some authors advocate the use of radiosurgery in the resection cavity when WBRT is withheld,⁵⁴ though this is controversial.

Table 3: Randomized Trials of WBRT + SRS Versus WBRT Alone or SRS Alone

First Author	Management Modalities	No. of Tumors	Maximum Tumor Size	Patient No.	Patient Eligibility	Median Survival (Months)	Statistical Significance
Andrews 2004 ²	WBRT	1-3	4 cm	94	Pts with prior surgery included, Pts with active disease excluded. WBRT 37.5 Gy in 15 fractions; SRS 15-24 Gy, linear accelerator or GK.	4.9	p = 0.0393
	WBRT + SRS			92		6.5	
Kondziolka 1999 ⁵⁶	WBRT	2-4	2.5 cm	14	Pts with active disease included. WBRT 30 Gy in 12 fractions.	7.5	p = 0.22
	WBRT + SRS			13		11	
Chougule 2000 ²³	SRS	1-3	3 cm	36	Pts with minimum life expectancy of 3 months were included. WBRT: 30 Gy in 10 fractions. SRS: 30 Gy to tumor margin. SRS + WBRT: SRS 20 Gy to margin + WBRT 30 Gy in 10 fractions.	7	NA
	WBRT + SRS			37		5	
	WBRT			31		9	
Aoyama 2006 ⁴	SRS	≤ 4	2 cm	60	30 Gy in 10 fractions over 2-2.5 weeks. Pts with SCC, lymphoma, germinoma and multiple myeloma were excluded.	7.5	p = 0.42
	WBRT + SRS			60		8	

Local Brain Tumor Control

There have been three randomized trials examining the use of whole-brain radiation therapy plus radiosurgery boost compared with whole-brain radiation therapy alone in selected patients with brain metastases. Two of these trials have been reported in the peer-reviewed published literature,^{2,56} and one has only been reported in abstract form with the final report pending.²³ In addition, one randomized trial has been published comparing radiosurgery with WBRT to radiosurgery alone.⁴

The RTOG 95-08 trial² randomized 164 patients to WBRT and radiosurgery boost and 167 patients to WBRT alone. Patients with one to three newly diagnosed brain metastases were included. The arms of the trial were well balanced for baseline characteristics known to affect survival such as age, Karnofsky Performance Status and status of extracranial metastases. Brain metastases with the largest lesion up to a maximum diameter of 4 cm and additional tumors less than 3 cm in size were included. Local brain control was defined as unchanged or improved on serial post-treatment MRI scans. Magnetic resonance imaging scans were judged in central review by one neuroradiologist as complete response, partial response or stable disease. Progressive disease was defined as an increase in the size of any lesion, development of new intracranial lesions, or stable disease with deterioration of the neurologic examination.

Kondziolka et al.⁵⁶ randomized patients with two to four brain metastases (all ≤ 25 mm) to WBRT alone (30 Gy in 12 fractions) or WBRT plus radiosurgery. The study was discontinued at 60% accrual when only 27 patients were randomized. The results were reported for 14 patients in the WBRT group and 13 patients in the WBRT and radiosurgery boost group. The two groups were well balanced with respect to age, sex, tumor type, number of tumors and extent of extracranial disease. Local brain control was defined as no tumor growth based on MRI scans and no increase in clinical symptoms associated with the lesion. Serial scans were read by an independent blinded observer. The Chougule et al. trial²³ randomized patients with one to three brain metastases to Gamma Knife[®] radiosurgery alone (30 Gy to the tumor margin), WBRT (30 Gy in 10 fractions) plus Gamma Knife[®] boost (20 Gy to the tumor margin), and WBRT alone (30 Gy in 10 fractions). Patients with tumor volume ≤ 30 cc and minimum life expectancy of > 3 months were included. Overall median survival was seven, five and nine months for the arms, respectively (not statistically significant). The results of this trial were published only in abstract form. Local brain control was not defined in the abstract.²³

In summary, three randomized trials^{2,23,55} detected an improvement in local brain control in patients treated with WBRT and radiosurgery boost compared with WBRT alone. Local brain control at one year ranged from 82–92% in the radiosurgery boost arm vs. 0–71% in the WBRT alone arm. The study by Kondziolka et al.⁵⁶ also noted superior intracranial control with the use of radiosurgery.

Aoyama et al. published the results of a prospective randomized trial of radiosurgery followed by WBRT versus radiosurgery alone.⁴ Local control rates with combined modality therapy were significantly better than with radiosurgery alone. The combination of the two therapeutic modalities provided a local control benefit similar to that seen in the combined modality arm of RTOG 95-08 (89% and 82%, respectively), demonstrating inter-study consistency.

Overall Survival

No statistically significant improvement in overall survival with the use of radiosurgery boost compared with WBRT alone was reported in these trials.^{2,23,55} However, RTOG 95-08² reported that WBRT and radiosurgery boost improved survival in RPA Class I patients and in patients with favorable histologic status, squamous cell or non-small cell lung tumors. Median survivals for the WBRT arm ranged from 5.7–7.5 months and for the WBRT and radiosurgery boost arm ranged from 5–11 months.

The RTOG 95-08 trial² reported that the overall mean survival time was 6.5 months for WBRT alone and 5.7 months for WBRT plus a radiosurgery boost ($p = 0.1356$). In Kondziolka et al.'s study,⁵⁶ median survival was not statistically different between the two groups (7.5 months for WBRT alone vs. 11 months for WBRT and radiosurgery boost [$p = 0.22$]). Survival was dependent on the extent of extracranial disease ($p = 0.02$) but was not dependent on histology or number of tumors.

The RTOG 95-08² used recursive partitioning analysis of prognostic factors⁴¹ to analyze the relative contributions of pretreatment variables on the survival of patients and to identify subgroups of patients with homogeneous prognostic characteristics predictive of survival. The three classes were: Class I, patients with KPS ≥ 70 , < 60 years of age with controlled primary and no extracranial metastases; Class III, KPS < 70 ; and Class II, all others. From the historic database, the best survival was noted in Class I patients (median, 7.1 months), intermediate in class II patients (median, 4.2 months), and the worst in Class III patients (median, 2.3 months). The RTOG 95-08 trial² explored survival outcomes in certain subsets of patients. By multivariate analysis, WBRT and radiosurgery boost improved survival in RPA Class I patients ($p < 0.0001$) and in patients with favorable histologic status, squamous cell or non-small cell lung tumors ($p = 0.0121$). In patients with single brain metastases (unresectable or inoperable) the median survival was 6.5 months with radiosurgery boost compared with 4.9 months with WBRT alone ($p = 0.0393$).

Quality of Life

The RTOG 95-08 trial² reported that patients in the radiosurgery boost group were more likely to have a stable or improved KPS at six months follow-up than patients in the WBRT alone group (43% vs. 27%, respectively, $p = 0.03$). Steroid use six months after treatment decreased in 41 of 76 patients treated with radiosurgery boost, compared with 25 of 75 patients treated with WBRT alone ($p = 0.0158$). Auchter et al., in a retrospective study,⁵ reported on quality

of life or symptom control outcomes. In this study,⁵ the median time in which the KPS was sustained ≥ 70 was 44 weeks for patients treated with WBRT and radiosurgery.

Complications

The Kondziolka et al. trial⁵⁶ reported “no neurologic or systemic morbidity related to [radiosurgery].” Andrews et al.² reported a statistically nonsignificant increase in the risk of toxicity with radiosurgery boost, which was 3% acute Grades 3 and 4 toxicities and 6% late Grades 3 and 4 toxicities. However, overall quality of life using a validated instrument was not measured in any of these trials.

Conclusion

There is Level I evidence (three randomized trials) that radiosurgery boost with WBRT, compared with WBRT alone, significantly improves local brain control rate for patients with up to four metastases. There is Level I evidence to indicate that radiosurgery boost with WBRT improves survival in selected patients with a single brain metastasis, and there is Level I evidence that the ability to taper down steroid dose and improvement of KPS was statistically better in the radiosurgery arm at six months.²

Radiosurgery Alone as Initial Therapy: Level I Evidence

Local Tumor Control

In a randomized trial reported in abstract form by Chougule et al.,²³ patients were randomized to Gamma Knife[®] radiosurgery alone vs. WBRT and Gamma Knife[®] radiosurgery vs. WBRT alone. The local brain control rate was higher in the two radiosurgery arms: 87% for Gamma Knife[®] radiosurgery alone and 91% for Gamma Knife[®] radiosurgery and WBRT, compared with 62% in the WBRT only arm.

Another randomized trial compared the use of radiosurgery with WBRT plus radiosurgery as initial therapy in selected patients with brain metastases.⁴ Aoyama et al. reported the results of a prospective, multi-institutional, randomized controlled trial comparing WBRT plus SRS vs. SRS alone for patients with limited (defined as ≤ 4) brain metastases with a maximum diameter of 3 cm on contrast-enhanced MRI scan.⁴ Patients with metastases from small cell carcinoma, lymphoma, germinoma and multiple myeloma were excluded. Eligible patients had a KPS score of 70 or higher. The WBRT dosage schedule was 30 Gy in 10 fractions over 2–2.5 weeks. Metastases with a maximum diameter of up to 2 cm were treated with SRS doses of 22–25 Gy and those larger than 2 cm were treated with doses of 18–20 Gy. The dose was reduced by 30% when the treatment was combined with WBRT. Local tumor progression was defined as a radiographic increase of 25% or more in the size of a metastatic lesion. The primary end point of the study was overall survival. Secondary end points were cause of death, functional preservation, brain tumor recurrence, salvage treatment and toxic effects of radiation. One hundred thirty-two patients were randomized (65 to WBRT + SRS and 67 to SRS alone). The interim analysis was performed with 122 patients (approximately 60 in each group). The Japanese Radiation Oncology Study Group 99-1 trial⁴ reported an

actuarial one-year local tumor control rate of 88.7% in the WBRT + SRS group and 72.5% in the SRS-alone group ($p = 0.002$). The one-year actuarial rate of developing new brain metastases was 41.5% in the WBRT + SRS group and 63.7% in the SRS-alone group ($p = 0.003$).

A prospective, single arm, multi-institutional Eastern Cooperative Oncology Group (ECOG) Phase II study of radiosurgery alone for “radioresistant” histologies (melanoma, sarcoma, renal cell carcinoma) in patients with one to three brain metastases has also been reported.⁶⁹ Inclusion criteria were one to three newly diagnosed brain metastases with a maximum diameter of 4 cm. In patients with multiple lesions and any lesion > 3 cm, all remaining lesions were required to be ≤ 3 cm. Of 36 patients accrued, 31 were eligible and evaluable; 14 had melanoma, 14 had renal cell carcinoma and three had sarcoma. Three of thirty-one patients (10%) had partial response, 10 of 31 (32%) had stable disease, 14 of 31 (42%) had progressive disease, and 4 of 31 (14%) were not evaluable. At six months, 39.2% failed within the radiosurgery volume and 39.4% failed outside the radiosurgery volume.

Several retrospective studies^{21,94,113,117,128} compared local brain control rates of those patients receiving initial radiosurgery alone with those receiving whole-brain radiation therapy. Chidel et al.²¹ found a statistically significant improvement in two-year brain control with the use of WBRT in addition to radiosurgery boost: 80% vs. 52% in patients treated with radiosurgery alone ($p = 0.034$). Pirzkall et al.⁹⁴ found one-year local control rates to be inferior with the radiosurgery alone group: 89% vs. 92% in the WBRT and radiosurgery boost group. Shehata et al.¹¹³ reported that patients who had whole-brain radiation therapy had superior local tumor control rates (97%) compared with patients treated with radiosurgery alone (87%; $p = 0.0001$). Sneed et al.¹¹⁷ reported a statistically significant improvement in one-year brain freedom from progression rate in those patients treated with WBRT + SRS boost (69%) compared with those patients treated with initial radiosurgery only (28%). It was commented that the one-year brain control rate allowing for salvage (using WBRT or serial SRS) at first failure was not statistically different between those treated with initial WBRT + SRS boost (73%) vs. those treated initially with SRS alone (62%). Wang et al.¹²⁸ found that the local brain control rate of patients treated with SRS alone was 93.3%, compared with 95.6% in patients treated with WBRT + SRS boost.

Survival

The Japanese trial⁴ found no significant survival difference between the groups receiving WBRT + SRS and SRS alone. The median survival time was 7.5 months with WBRT + SRS and 8.0 months with SRS alone. In addition, no significant difference in the frequency of death due to neurologic causes was observed. Death was attributed to neurologic causes in 22.8% in the WBRT + SRS group and in 19.3% in the SRS alone group. In Chougule et al.’s abstract,²³ median survivals were seven, five and nine months for Gamma Knife[®] radiosurgery alone vs. WBRT and Gamma Knife[®] radiosurgery vs. WBRT, respectively. Survival was reported as not different among the three arms. The ECOG

Phase II trial⁶⁹ of radiosurgery alone for radioresistant histologies found median survival to be 8.2 months (95% CI, 7.4–12.2 months) in its cohort of patients.

Lutterbach performed a prospective study⁶⁶ using radiosurgery alone for the initial management of brain metastases. However, no survival comparisons were made with patients treated with WBRT. Several retrospective studies have reported on the use of radiosurgery alone as initial management of selected patients with brain metastases.^{15,21,39,49,53,105,109,113,115,117,118,124,128} Survival outcomes ranged from 8–15 months. Chidel et al.²¹ reported the median survival of patients treated with radiosurgery alone as 10.5 months compared with 6.4 months in patients treated with radiosurgery boost and whole-brain radiation therapy (p value not stated). Sneed et al.¹¹⁷ reported that the median survival of patients treated initially with radiosurgery alone was 11.3 months, which was not statistically different from the survival of patients treated with WBRT + SRS boost (11.1 months). Wang et al.¹²⁸ reported a median survival of 15 months in patients treated with SRS alone vs. 20 months in patients treated with WBRT + SRS boost vs. 8.5 months for patients treated with WBRT alone.

Pirzkall et al.⁹⁴ found no difference in overall survival for patients treated with radiosurgery alone or radiosurgery and WBRT; however, in the subset of patients without extracranial disease, omitting whole-brain radiation therapy resulted in a survival decrement from 15.4 to 8.3 months. Sneed et al.¹¹⁸ collected data from 10 institutions to compare the survival probabilities of patients with newly diagnosed brain metastases managed initially with SRS alone vs. SRS and WBRT. Of the 569 evaluable patients, 268 had radiosurgery alone initially (24% of these ultimately needed salvage WBRT) and 301 had radiosurgery and up-front WBRT. The median survival times for patients treated with SRS initially vs. SRS + WBRT were 14.0 vs. 15.2 months for RPA Class I, 8.2 vs. 7.0 months for Class II, and 5.3 vs. 5.5 months for Class III. With adjustment by RPA class, there was no survival difference comparing radiosurgery alone initially with radiosurgery and up-front whole-brain radiation therapy.

There is Level I evidence from the recently published Japanese trial⁴ and Level II-3 evidence from literature that addition of up-front WBRT does not improve survival in patients treated with up-front radiosurgery. Thus patients with newly diagnosed brain metastases can be treated with up-front SRS alone, reserving WBRT for salvage.

Quality of Life or Symptom Control

No formal comparisons between radiosurgery alone vs. competing options of management such as WBRT have been made in terms of quality of life or symptom control among the studies. The only study that has reported KPS outcomes has been the Japanese randomized trial.⁴ Actuarial one-year KPS preservation rate (KPS \geq 70) was 25% in the SRS alone arm and 37% in the WBRT + SRS arm. No formal neurologic functional tests were prospectively performed. However, validated quality of life outcomes have not been reported in any of these studies examining the use of radiosurgery alone

(without whole-brain radiation therapy) as up-front treatment for brain metastases.

Complications

In the randomized Japanese trial,⁴ there was no statistically significant difference in any grade of either acute or late radiation toxicities between the radiosurgery alone arm and the radiosurgery and whole-brain radiation therapy arm. In the ECOG trial,⁶⁹ two Grade 3 events in 31 patients (one seizure and one fatigue) were thought to be possibly related to radiosurgery. The prospective study by Lutterbach et al.⁶⁶ reported 13% of patients experiencing complications with radiosurgery alone as initial treatment for brain metastases. Nine percent were acute toxicities and 4% were late toxicities. Varying degrees of toxicities were reported in the retrospective series examining the outcomes of patients treated with radiosurgery alone.

Conclusion

There is Level I to Level II-3 evidence that addition of WBRT in patients treated with radiosurgery for 1–3 newly diagnosed brain metastases does not improve survival, compared with radiosurgery alone with WBRT reserved for salvage therapy. There is Level I evidence that omission of WBRT results in decreased tumor control, both at the site of radiosurgery and also in the remaining untreated brain. Level II-1 and Level II-3 evidence further support this observation.

Other Management Strategies

Chemotherapy

In principle the use of chemotherapy for brain metastases is appealing because it can treat multiple brain tumors as well as systemic cancer. The neurocognitive profile after chemotherapy is better than with WBRT. However, the development of brain metastases while patients are undergoing systemic chemotherapy indicates that the blood-brain barrier makes the brain a sanctuary from many chemotherapeutic agents. The tight intercellular junctions of the BBB prevent the free passage of drugs into brain parenchyma and CSF. However, some chemotherapeutic agents do cross the intact BBB fairly well. Such agents include the nitrosoureas (e.g., BCNU and CCNU), thiotepa and temozolomide. Topotecan, irinotecan and hydroxyfosphamide are also probably effective. High-dose methotrexate and cytarabine, etoposide and idarubicin do not cross the BBB well but may still achieve cytotoxic CSF concentrations. Several studies have examined the use of chemotherapy in brain metastases and have shown promise for patients with brain metastases from small cell lung cancer,^{3,46,60,96} breast cancer^{38,175} and germ cell tumors. Brain metastases from NSCLC are generally less chemosensitive than those from SCLC.³¹ In summary, despite concerns about the BBB, which plays a role in allowing development of brain metastases in patients undergoing systemic chemotherapy, there is good evidence that systemic chemotherapy is sometimes useful in managing brain metastases. Its role will be limited to patients with multiple brain metastases or active systemic cancer reasonably likely to respond to chemotherapy. The optimal drugs, schedule and route of administration remain to be determined.

Local Delivery of Radiation or Drug at the Time of Surgery

Local radiation techniques, such as brachytherapy with I¹²⁵ seeds and inflatable balloon catheters utilizing a liquid I¹²⁵ (GliaSite® Radiation Therapy System), are being evaluated for resectable brain metastases. GliaSite® consists of an inflatable balloon catheter that is inserted into resection cavities at the completion of surgery. Radiation is delivered with an aqueous solution of organically bound I¹²⁵ (Iotrex® [sodium 3-(¹²⁵I)-iodo-4-hydroxybenzenesulfonate]), which is temporarily introduced into the balloon portion of the device via a subcutaneous port approximately 5–14 days following surgery. The I¹²⁵ is uniformly distributed within the treatment balloon and provides radiation to the surrounding brain parenchyma. The Iotrex® is typically allowed to dwell in the device for 3–6 days, after which the device is explanted. Complications associated with GliaSite® are reported to include pseudomeningocele development, wound infection and meningitis. The GliaSite® system remains an option for the treatment of newly diagnosed or potentially recurrent metastases when other forms of treatment have failed.⁷² In addition, a Phase II study of GliaSite® brachytherapy after resection of a single metastasis has demonstrated local control rate, median patient survival time, and duration of functional independence similar to that achieved with resection plus whole-brain radiation therapy.¹⁰¹ GliaSite® can be particularly useful for tumors with volumes too large to permit radiosurgery.

Gliadel® wafers (BCNU biodegradable polymer wafers) have been developed as a method of optimizing drug delivery into the CNS with satisfactory safety and efficacy without producing undesirable systemic side effects. The chemotherapy wafers are implanted in the tumor resection cavity at the completion of surgery.¹³ Gliadel® was found to be effective in breast cancer without subsequent administration of radiotherapy.^{34,35} Local BCNU administration was also shown to be effective.³⁴ Local therapies delivered at the time of surgical resection of brain metastases hold promise but have yet to be rigorously proven to provide benefit for patients with brain metastases.

Targeted Therapies for Brain Metastases

Significant advances have been made in the understanding of the molecular and cellular biology of normal and cancerous cells. Molecular abnormalities include chromosomal aberrations, which can result in overexpression of oncogenes or inhibition of tumor suppressor genes. On a cellular level, abnormalities of growth factor regulation, signaling pathway dysregulation, and dedifferentiation have all been implicated in malignant progression. The metastatic phenotype is also associated with abnormal angiogenesis and invasion. All of these molecular and cytogenetic abnormalities are potential targets for therapy. A detailed discussion of targeted therapy for brain metastases is complex and beyond the scope of these guidelines. Several agents have been developed to target pathways that are critical for the ongoing growth and proliferation of cancer. Many of these signaling pathways are involved in critical cellular events, including DNA repair, cell survival signals, invasion, angiogenesis, metastasis and apoptosis. In the future these pathways may play an important role in

mediating sensitivity to chemotherapy and radiation therapy. There is increasing evidence that the newer biologic agents targeting cellular protein receptors or other components of the tumor microenvironment may work synergistically with conventional radiation and cytotoxic agents.

Repeat Radiosurgery

Since tumor control rate after radiosurgery is 80–90%, other management options after radiosurgery may be needed for patients with documented tumor growth. Whole-brain radiation therapy, microsurgery, and in selected cases repeat radiosurgery, can be considered for patients with tumor growth despite radiosurgery. Very little data are available on repeat radiosurgery for brain metastases.⁸

Indications for Radiosurgery

- Newly diagnosed single or multiple brain metastases without significant mass effect documented on imaging
- Boost after WBRT for single or multiple brain metastases
- Recurrent brain metastases after WBRT
- Radiosurgery for residual tumor after resection

Clinical Algorithm

Several factors are considered in making a recommendation. These factors include:

1. Patient's age
2. Patient's symptoms
3. Status of systemic disease
4. Patient's current neurological status
5. Patient's medical condition
6. Presence or absence of other organ metastases
7. History of prior WBRT
8. History of prior brain procedures
9. Patient's concern and risk tolerance for neuro-cognitive functions
10. Patient's wishes

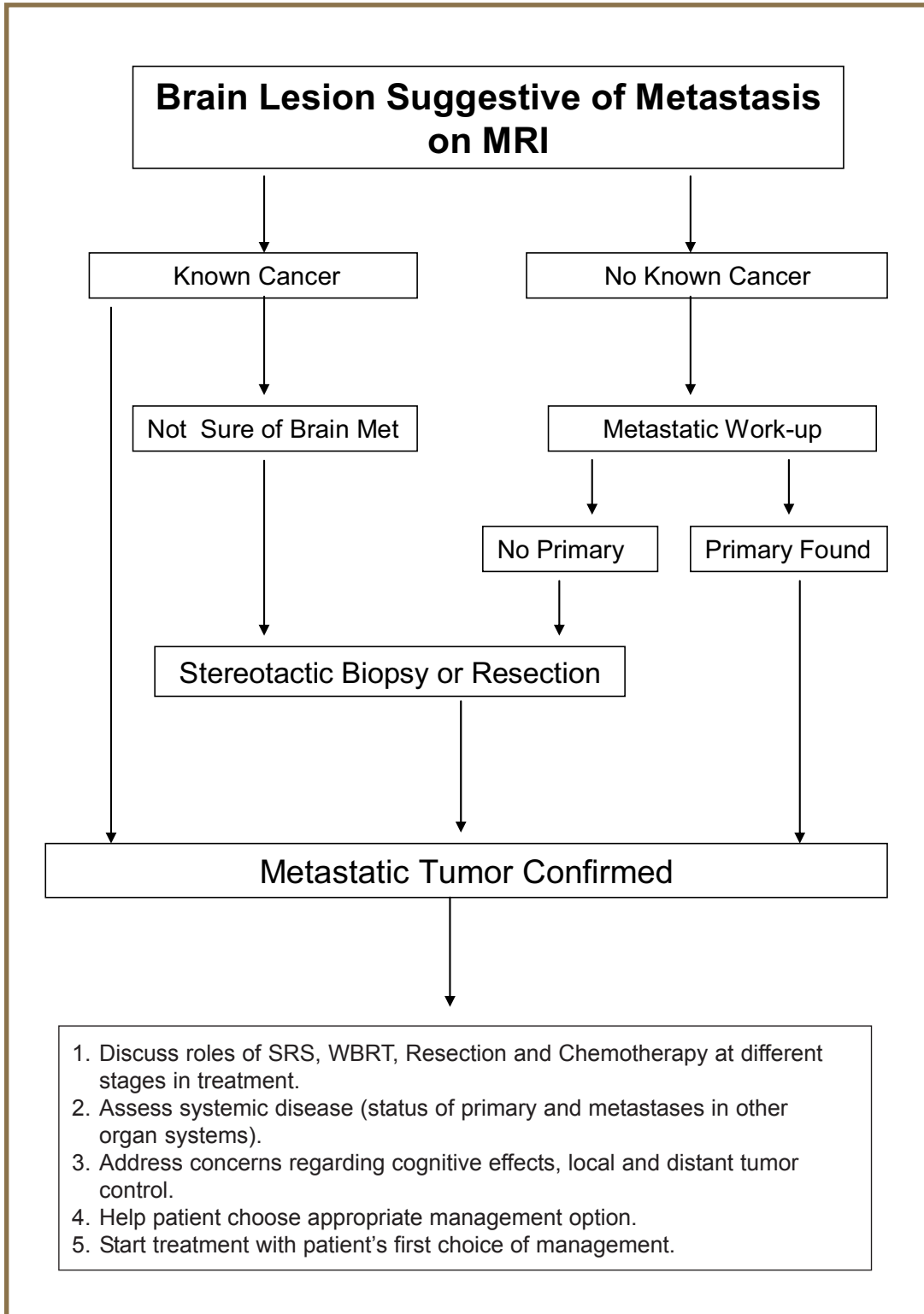
Tumor Size

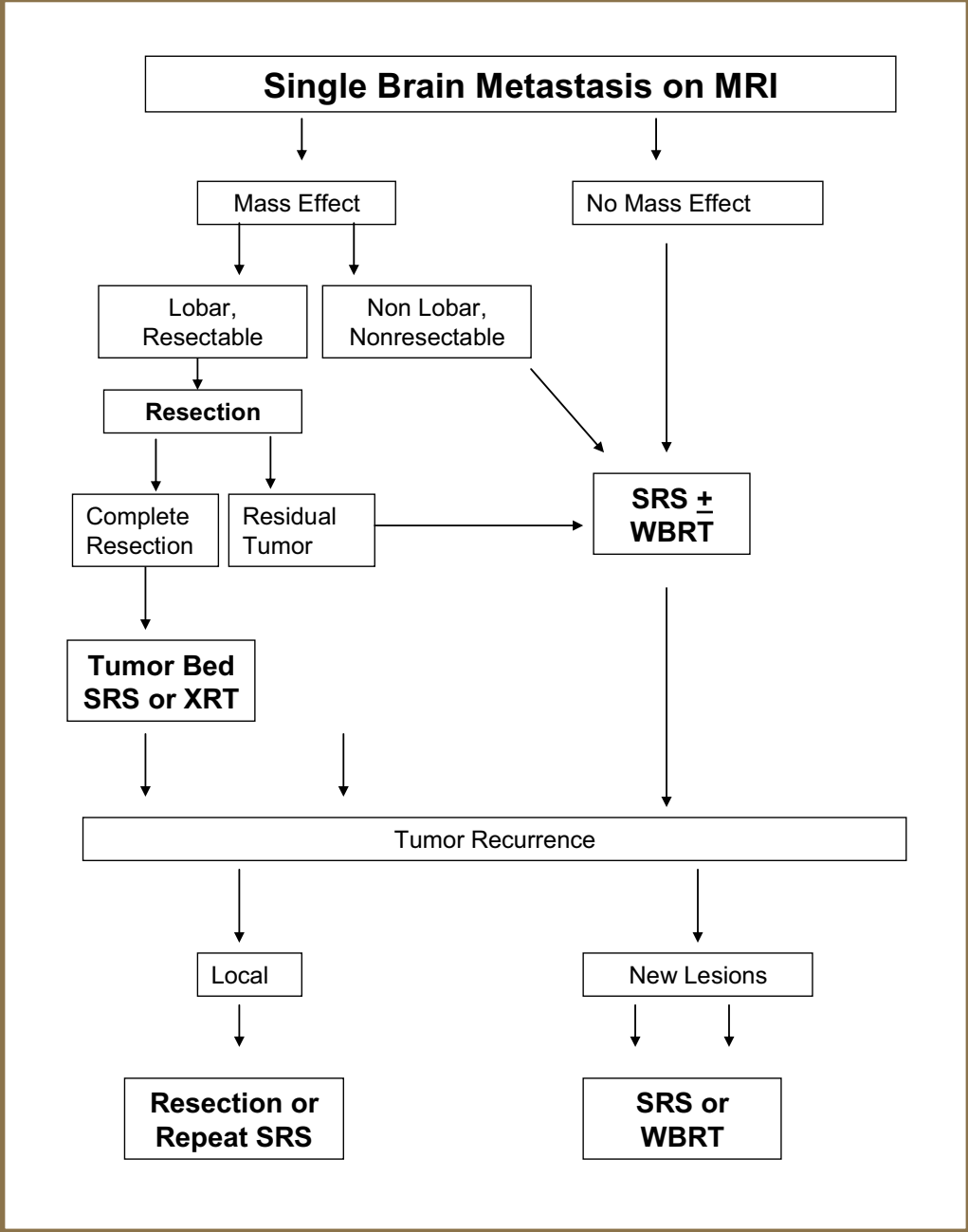
Radiosurgery can be performed for tumors up to 4 cm in maximum diameter. However, tumor volume, dose and location are more important variables.

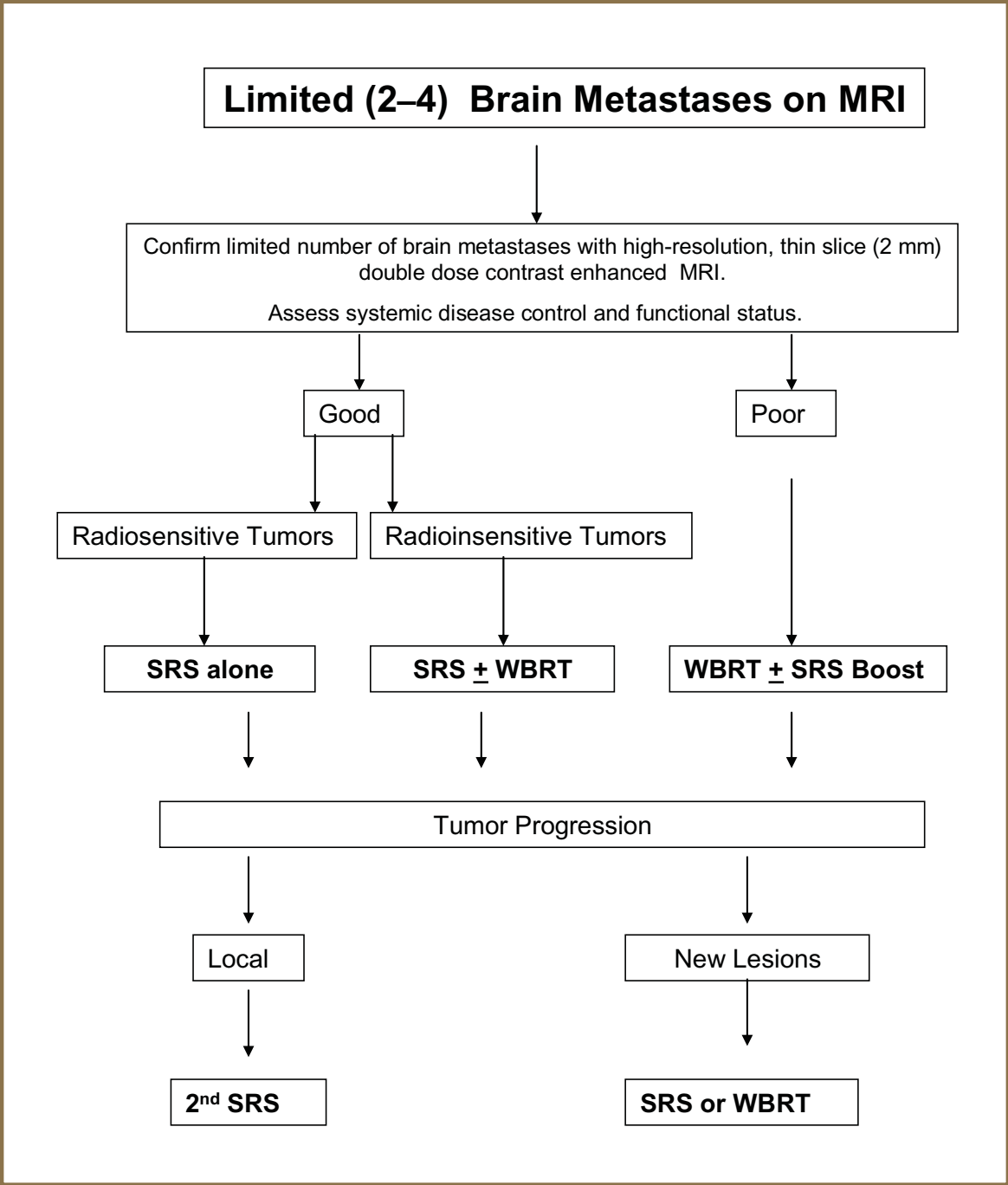
Patient Preference

Patients' preferences are also considered in selecting a management approach.

A broad outline of brain metastases diagnostic work-up and management algorithms for single tumor, limited brain disease (2–4 tumors) and multiple metastases are shown. However, the final recommendation is usually influenced by the recommending surgeon's, radiation oncologist's and neuro-oncologist's experiences along with patient preference.







Multiple (>4) Brain Metastases on MRI

Conventional Management

WBRT

Progression

SRS

Limited WBRT Boost

Emerging Strategies

SRS + WBRT

Progression

Repeat SRS

Limited WBRT Boost

References

- Amendola BE, Wolf AL, Coy SR, Amendola M, Bloch L: Gamma knife radiosurgery in the treatment of patients with single and multiple brain metastases from carcinoma of the breast. **Cancer J** **6**:88-92, 2000
- Andrews DW, Scott CB, Sperduto PW, Flanders AE, Gaspar LE, Schell MC, et al: Whole brain radiation therapy with or without stereotactic radiosurgery boost for patients with one to three brain metastases: phase III results of the RTOG 9508 randomised trial. **Lancet** **363**:1665-1672, 2004
- Antonadou D, Paraskevaidis M, Sarris G, Coliarakis N, Economou I, Karageorgis P, et al: Phase II randomized trial of temozolomide and concurrent radiotherapy in patients with brain metastases. **J Clin Oncol** **20**:3644-3650, 2002
- Aoyama H, Shirato H, Tago M, Nakagawa K, Toyoda T, Hatano K, et al: Stereotactic radiosurgery plus whole-brain radiation therapy vs stereotactic radiosurgery alone for treatment of brain metastases: a randomized controlled trial. **Jama** **295**:2483-2491, 2006
- Auchter RM, Lamond JP, Alexander E, Buatti JM, Chappell R, Friedman WA, et al: A multiinstitutional outcome and prognostic factor analysis of radiosurgery for resectable single brain metastasis. **Int J Radiat Oncol Biol Phys** **35**:27-35, 1996
- Barnholtz-Sloan JS, Sloan AE, Davis FG, Vignea FD, Lai P, Sawaya RE: Incidence proportions of brain metastases in patients diagnosed (1973 to 2001) in the Metropolitan Detroit Cancer Surveillance System. **J Clin Oncol** **22**:2865-2872, 2004
- Bendell JC, Domchek SM, Burstein HJ, Harris L, Younger J, Kuter I, et al: Central nervous system metastases in women who receive trastuzumab-based therapy for metastatic breast carcinoma. **Cancer** **97**:2972-2977, 2003
- Bhatnagar A, Heron DE, Kondziolka D, Lunsford LD, Flickinger JC: Analysis of repeat stereotactic radiosurgery for progressive primary and metastatic CNS tumors. **Int J Radiat Oncol Biol Phys** **53**:527-532, 2002
- Bhatnagar AK, Flickinger JC, Kondziolka D, Lunsford LD: Stereotactic radiosurgery for four or more intracranial metastases. **Int J Radiat Oncol Biol Phys** **64**:898-903, 2006
- Bhatnagar AK, Kondziolka D, Lunsford LD, Flickinger JC: Recursive partitioning analysis of prognostic factors for patients with four or more intracranial metastases treated with radiosurgery. **Technol Cancer Res Treat** **6**:153-160, 2007
- Bindal RK, Sawaya R, Leavens ME, Lee JJ: Surgical treatment of multiple brain metastases. **J Neurosurg** **79**:210-216, 1993
- Borgelt B, Gelber R, Kramer S, Brady LW, Chang CH, Davis LW, et al: The palliation of brain metastases: final results of the first two studies by the Radiation Therapy Oncology Group. **Int J Radiat Oncol Biol Phys** **6**:1-9, 1980
- Brem H, Piantadosi S, Burger PC, Walker M, Selker R, Vick NA, et al: Placebo-controlled trial of safety and efficacy of intraoperative controlled delivery by biodegradable polymers of chemotherapy for recurrent gliomas. The Polymer-brain Tumor Treatment Group. **Lancet** **345**:1008-1012, 1995
- Chambers AF, MacDonald IC, Schmidt EE, Morris VL, Groom AC: Clinical targets for anti-metastasis therapy. **Adv Cancer Res** **79**:91-121, 2000
- Chang EL, Hassenbusch SJ 3rd, Shiu AS, Lang FF, Allen PK, Sawaya R, et al: The role of tumor size in the radiosurgical management of patients with ambiguous brain metastases. **Neurosurgery** **53**:272-280; discussion 280-281, 2003
- Chang EL, Selek U, Hassenbusch SJ 3rd, Maor MH, Allen PK, Mahajan A, et al: Outcome variation among "radioresistant" brain metastases treated with stereotactic radiosurgery. **Neurosurgery** **56**:936-945; discussion 936-945, 2005
- Chang EL, Wefel JS, Maor MH, Hassenbusch SJ 3rd, Mahajan A, Lang FF, et al: A pilot study of neurocognitive function in patients with one to three new brain metastases initially treated with stereotactic radiosurgery alone. **Neurosurgery** **60**:277-283; discussion 283-284, 2007
- Chang JE, Robins HI, Mehta MP: Therapeutic advances in the treatment of brain metastases. **Clin Adv Hematol Oncol** **5**:54-64, 2007
- Chao ST, Suh JH, Raja S, Lee SY, Barnett G: The sensitivity and specificity of FDG PET in distinguishing recurrent brain tumor from radionecrosis in patients treated with stereotactic radiosurgery. **Int J Cancer** **96**:191-197, 2001
- Chernov MF, Nakaya K, Izawa M, Hayashi M, Usuba Y, Kato K, et al: Outcome after radiosurgery for brain metastases in patients with low Karnofsky performance scale (KPS) scores. **Int J Radiat Oncol Biol Phys** **67**:1492-1498, 2007
- Chidel MA, Suh JH, Reddy CA, Chao ST, Lundbeck MF, Barnett GH: Application of recursive partitioning analysis and evaluation of the use of whole brain radiation among patients treated with stereotactic radiosurgery for newly diagnosed brain metastases. **Int J Radiat Oncol Biol Phys** **47**:993-999, 2000
- Chitapanarux I, Goss B, Vongtama R, Frighetto L, De Salles A, Selch M, et al: Prospective study of stereotactic radiosurgery without whole brain radiotherapy in patients with four or less brain metastases: incidence of intracranial progression and salvage radiotherapy. **J Neurooncol** **61**:143-149, 2003
- Chougule PB, Burton-Williams M, Saris S, Zheng Z, Ponte B, Norén G, et al: Randomized treatment of brain metastasis with gamma knife radiosurgery, whole brain radiotherapy or both. **Int J Radiat Oncol Biol Phys** **48**(Suppl 1):114, 2000
- Coffey RJ, Flickinger JC, Bissonette DJ, Lunsford LD: Radiosurgery for solitary brain metastases using the cobalt-60 gamma unit: methods and results in 24 patients. **Int J Radiat Oncol Biol Phys** **20**:1287-1295, 1991
- Cormio G, Maneo A, Colamaria A, Loverro G, Lissoni A, Selvaggi L: Surgical resection of solitary brain metastasis from ovarian carcinoma: an analysis of 22 cases. **Gynecol Oncol** **89**:116-119, 2003

26. DeAngelis LM, Delattre JY, Posner JB: Radiation-induced dementia in patients cured of brain metastases. **Neurology** **39**:789-796, 1989
27. Decker DA, Decker VL, Herskovic A, Cummings GD: Brain metastases in patients with renal cell carcinoma: prognosis and treatment. **J Clin Oncol** **2**:169-173, 1984
28. Delattre JY, Krol G, Thaler HT, Posner JB: Distribution of brain metastases. **Arch Neurol** **45**:741-744, 1988
29. DeYoung BR, Wick MR: Immunohistologic evaluation of metastatic carcinomas of unknown origin: an algorithmic approach. **Semin Diagn Pathol** **17**:184-193, 2000
30. DiLuna ML, King JT, Jr., Knisely JP, Chiang VL: Prognostic factors for survival after stereotactic radiosurgery vary with the number of cerebral metastases. **Cancer** **109**:135-145, 2007
31. Dziadziuszko R, Ardizzoni A, Postmus PE, Smit EF, Price A, Debruyne C, et al: Temozolomide in patients with advanced non-small cell lung cancer with and without brain metastases. a phase II study of the EORTC Lung Cancer Group (08965). **Eur J Cancer** **39**:1271-1276, 2003
32. Engh JA, Flickinger JC, Niranjan A, Amin DV, Kondziolka DS, Lunsford LD: Optimizing Intracranial Metastasis Detection for Stereotactic Radiosurgery. **Stereotact Funct Neurosurg** **85**:162-168, 2007
33. Epstein BE, Scott CB, Sause WT, Rotman M, Sneed PK, Janjan NA, et al: Improved survival duration in patients with unresected solitary brain metastasis using accelerated hyperfractionated radiation therapy at total doses of 54.4 gray and greater. Results of Radiation Therapy Oncology Group 85-28. **Cancer** **71**:1362-1367, 1993
34. Ewend MG, Sampath P, Williams JA, Tyler BM, Brem H: Local delivery of chemotherapy prolongs survival in experimental brain metastases from breast carcinoma. **Neurosurgery** **43**:1185-1193, 1998
35. Ewend MG, Williams JA, Tabassi K, Tyler BM, Babel KM, Anderson RC, et al: Local delivery of chemotherapy and concurrent external beam radiotherapy prolongs survival in metastatic brain tumor models. **Cancer Res** **56**:5217-5223, 1996
36. Farnell GF, Buckner JC, Cascino TL, O'Connell MJ, Schomberg PJ, Suman V: Brain metastases from colorectal carcinoma. The long term survivors. **Cancer** **78**:711-716, 1996
37. Flickinger JC, Kondziolka D, Lunsford LD, Coffey RJ, Goodman ML, Shaw EG, et al: A multi-institutional experience with stereotactic radiosurgery for solitary brain metastasis. **Int J Radiat Oncol Biol Phys** **28**:797-802, 1994
38. Franciosi V, Cocconi G, Michiara M, Di Costanzo F, Fossler V, Tonato M, et al: Front-line chemotherapy with cisplatin and etoposide for patients with brain metastases from breast carcinoma, nonsmall cell lung carcinoma, or malignant melanoma: a prospective study. **Cancer** **85**:1599-1605, 1999
39. Fukuoka S, Seo Y, Takanashi M, Takahashi S, Suematsu K, Nakamura J: Radiosurgery of brain metastases with the Gamma Knife. **Stereotact Funct Neurosurg** **66 Suppl 1**:193-200, 1996
40. Galanaud D, Nicoli F, Le Fur Y, Guye M, Ranjeva JP, Confort-Gouny S, et al: Multimodal magnetic resonance imaging of the central nervous system. **Biochimie** **85**:905-914, 2003
41. Gaspar L, Scott C, Rotman M, Asbell S, Phillips T, Wasserman T, et al: Recursive partitioning analysis (RPA) of prognostic factors in three Radiation Therapy Oncology Group (RTOG) brain metastases trials. **Int J Radiat Oncol Biol Phys** **37**:745-751, 1997
42. Gaudy-Marqueste C, Regis JM, Muracciole X, Laurans R, Richard MA, Bonerandi JJ, et al: Gamma-Knife radiosurgery in the management of melanoma patients with brain metastases: a series of 106 patients without whole-brain radiotherapy. **Int J Radiat Oncol Biol Phys** **65**:809-816, 2006
43. Gerosa M, Nicolato A, Foroni R, Tomazzoli L, Bricolo A: Analysis of long-term outcomes and prognostic factors in patients with non-small cell lung cancer brain metastases treated by gamma knife radiosurgery. **J Neurosurg** **102 Suppl**:75-80, 2005
44. Glantz MJ, Cole BF, Forsyth PA, Recht LD, Wen PY, Chamberlain MC, et al: Practice parameter: anticonvulsant prophylaxis in patients with newly diagnosed brain tumors. Report of the Quality Standards Subcommittee of the American Academy of Neurology. **Neurology** **54**:1886-1893, 2000
45. Graus F, Walker RW, Allen JC: Brain metastases in children. **J Pediatr** **103**:558-561, 1983
46. Grossi F, Scolaro T, Tixi L, Loprevite M, Ardizzoni A: The role of systemic chemotherapy in the treatment of brain metastases from small-cell lung cancer. **Crit Rev Oncol Hematol** **37**:61-67, 2001
47. Hammoud MA, McCutcheon IE, Elsouki R, Schoppa D, Patt YZ: Colorectal carcinoma and brain metastasis: distribution, treatment, and survival. **Ann Surg Oncol** **3**:453-463, 1996
48. Hankins JR, Miller JE, Salzman M, Ferraro F, Green DC, Attar S, et al: Surgical management of lung cancer with solitary cerebral metastasis. **Ann Thorac Surg** **46**:24-28, 1988
49. Hasegawa T, Kondziolka D, Flickinger JC, Germanwala A, Lunsford LD: Brain metastases treated with radiosurgery alone: an alternative to whole brain radiotherapy? **Neurosurgery** **52**:1318-1326; discussion 1326, 2003
50. Healy ME, Hesselink JR, Press GA, Middleton MS: Increased detection of intracranial metastases with intravenous Gd-DTPA. **Radiology** **165**:619-624, 1987
51. Hussain A, Brown PD, Stafford SL, Pollock BE: Stereotactic radiosurgery for brainstem metastases: Survival, tumor control, and patient outcomes. **Int J Radiat Oncol Biol Phys** **67**:521-524, 2007
52. Iwadate Y, Namba H, Yamaura A: Significance of surgical resection for the treatment of multiple brain metastases. **Anticancer Res** **20**:573-577, 2000
53. Joseph J, Adler JR, Cox RS, Hancock SL: Linear accelerator-based stereotaxic radiosurgery for brain metastases: the influence of number of lesions on survival. **J Clin Oncol** **14**:1085-1092, 1996
54. Kim PK, Ellis TL, Stieber VW, McMullen KP, Shaw EG, McCoy TP, et al: Gamma Knife surgery targeting the resection cavity of brain metastasis that has

- progressed after whole-brain radiotherapy. **J Neurosurg (Suppl)** **105**:75-78, 2006
55. Komarnicky LT, Phillips TL, Martz K, Asbell S, Isaacson S, Urtasun R: A randomized phase III protocol for the evaluation of misonidazole combined with radiation in the treatment of patients with brain metastases (RTOG-7916). **Int J Radiat Oncol Biol Phys** **20**:53-58, 1991
 56. Kondziolka D, Patel A, Lunsford LD, Kassam A, Flickinger JC: Stereotactic radiosurgery plus whole brain radiotherapy versus radiotherapy alone for patients with multiple brain metastases. **Int J Radiat Oncol Biol Phys** **45**:427-434, 1999
 57. Kurtz JM, Gelber R, Brady LW, Carella RJ, Cooper JS: The palliation of brain metastases in a favorable patient population: a randomized clinical trial by the Radiation Therapy Oncology Group. **Int J Radiat Oncol Biol Phys** **7**:891-895, 1981
 58. Lagerwaard FJ, Levendag PC, Nowak PJ, Eijkenboom WM, Hanssens PE, Schmitz PI: Identification of prognostic factors in patients with brain metastases: a review of 1292 patients. **Int J Radiat Oncol Biol Phys** **43**:795-803, 1999
 59. Landis SH, Murray T, Bolden S, Wingo PA: Cancer statistics, 1998. **CA Cancer J Clin** **48**:6-29, 1998
 60. Landonio G, Sartore-Bianchi A, Giannetta L, Renga M, Riva M, Siena S: Controversies in the management of brain metastases: the role of chemotherapy. **Forum (Genova)** **11**:59-74, 2001
 61. Lassman AB, DeAngelis LM: Brain metastases. **Neurol Clin** **21**:1-23, vii, 2003
 62. Lavine SD, Petrovich Z, Cohen-Gadol AA, Masri LS, Morton DL, O'Day SJ, et al: Gamma knife radiosurgery for metastatic melanoma: an analysis of survival, outcome, and complications. **Neurosurgery** **44**:59-64; discussion 64-56, 1999
 63. Lippitz BE, Kraepelien T, Hautanen K, Ritzling M, Rah T, Ulfarsson E, et al: Gamma knife radiosurgery for patients with multiple cerebral metastases. **Acta Neurochir Suppl** **91**:79-87, 2004
 64. Loeffler JS, Kooy HM, Wen PY, Fine HA, Cheng CW, Mannarino EG, et al: The treatment of recurrent brain metastases with stereotactic radiosurgery. **J Clin Oncol** **8**:576-582, 1990
 65. Long DM: Capillary ultrastructure in human metastatic brain tumors. **J Neurosurg** **51**:53-58, 1979
 66. Lutterbach J, Cyron D, Henne K, Ostertag CB: Radiosurgery followed by planned observation in patients with one to three brain metastases. **Neurosurgery** **52**:1066-1073; discussion 1073-1074, 2003
 67. Magilligan DJ Jr., Duvernoy C, Malik G, Lewis JW, Jr., Knighton R, Ausman JI: Surgical approach to lung cancer with solitary cerebral metastasis: twenty-five years' experience. **Ann Thorac Surg** **42**:360-364, 1986
 68. Mamelak AN, Withers GJ, Wang X: Choriocarcinoma brain metastasis in a patient with viable intrauterine pregnancy. Case report. **J Neurosurg** **97**:477-481, 2002
 69. Manon R, O'Neill A, Knisely J, Werner-Wasik M, Lazarus HM, Wagner H, et al: Phase II trial of radiosurgery for one to three newly diagnosed brain metastases from renal cell carcinoma, melanoma, and sarcoma: an Eastern Cooperative Oncology Group study (E 6397). **J Clin Oncol** **23**:8870-8876, 2005
 70. Mathieu D, Kondziolka D, Cooper PB, Flickinger JC, Niranjana A, Agarwala S, et al: Gamma knife radiosurgery in the management of malignant melanoma brain metastases. **Neurosurgery** **60**:471-481; discussion 481-482, 2007
 71. Mavrakis AN, Halpern EF, Barker FG 2nd, Gonzalez RG, Henson JW: Diagnostic evaluation of patients with a brain mass as the presenting manifestation of cancer. **Neurology** **65**:908-911, 2005
 72. McDermott MW, Cosgrove GR, Larson DA, Sneed PK, Gutin PH: Interstitial brachytherapy for intracranial metastases. **Neurosurg Clin N Am** **7**:485-495, 1996
 73. Mehta M, Noyes W, Craig B, Lamond J, Auchter R, French M, et al: A cost-effectiveness and cost-utility analysis of radiosurgery vs. resection for single-brain metastases. **Int J Radiat Oncol Biol Phys** **39**:445-454, 1997
 74. Mehta MP, Gervais R, Chabot P: Motexafin gadolinium (MGd) combined with prompt whole brain radiation therapy (RT) prolongs time to neurologic progression in non-small cell lung cancer (NSCLC) patients with brain metastases: results of a phase III trial (Abstract). **J Clin Oncol** **24**:7014, 2006
 75. Mehta MP, Rodrigus P, Terhaard CH, Rao A, Suh J, Roa W, et al: Survival and neurologic outcomes in a randomized trial of motexafin gadolinium and whole-brain radiation therapy in brain metastases. **J Clin Oncol** **21**:2529-2536, 2003
 76. Mehta MP, Rozental JM, Levin AB, Mackie TR, Kubsad SS, Gehring MA, et al: Defining the role of radiosurgery in the management of brain metastases. **Int J Radiat Oncol Biol Phys** **24**:619-625, 1992
 77. Merchut MP: Brain metastases from undiagnosed systemic neoplasms. **Arch Intern Med** **149**:1076-1080, 1989
 78. Mintz A, Perry J, Spithoff K, Chambers A, Laperriere N: Management of single brain metastasis: a practice guideline. **Curr Oncol** **14**:131-143, 2007
 79. Mintz AH, Kestle J, Rathbone MP, Gaspar L, Hugenholtz H, Fisher B, et al: A randomized trial to assess the efficacy of surgery in addition to radiotherapy in patients with a single cerebral metastasis. **Cancer** **78**:1470-1476, 1996
 80. Muacevic A, Kreth FW, Horstmann GA, Schmid-Elsaesser R, Wowra B, Steiger HJ, et al: Surgery and radiotherapy compared with gamma knife radiosurgery in the treatment of solitary cerebral metastases of small diameter. **J Neurosurg** **91**:35-43, 1999
 81. Murray KJ, Scott C, Greenberg HM, Emami B, Seider M, Vora NL, et al: A randomized phase III study of accelerated hyperfractionation versus standard in patients with unresected brain metastases: a report of the Radiation Therapy Oncology Group (RTOG) 9104. **Int J Radiat Oncol Biol Phys** **39**:571-574, 1997
 82. Nam TK, Lee JI, Jung YJ, Im YS, An HY, Nam DH, et al: Gamma knife surgery for brain metastases in patients harboring four or more lesions: survival and

- prognostic factors. **J Neurosurg** **102 Suppl**:147-150, 2005
83. Nieder C, Nestle U, Motaref B, Walter K, Niewald M, Schnabel K: Prognostic factors in brain metastases: should patients be selected for aggressive treatment according to recursive partitioning analysis (RPA) classes? **Int J Radiat Oncol Biol Phys** **46**:297-302, 2000
 84. Nutt SH, Patchell RA: Intracranial hemorrhage associated with primary and secondary tumors. **Neurosurg Clin N Am** **3**:591-599, 1992
 85. Pan HC, Sheehan J, Stroila M, Steiner M, Steiner L: Gamma knife surgery for brain metastases from lung cancer. **J Neurosurg (Suppl)** **102**:128-133, 2005
 86. Patchell RA: Brain metastases. **Neurol Clin** **9**:817-824, 1991
 87. Patchell RA: Metastatic brain tumors. **Neurol Clin** **13**:915-925, 1995
 88. Patchell RA, Posner JB: Neurologic complications of systemic cancer. **Neurol Clin** **3**:729-750, 1985
 89. Patchell RA, Tibbs PA, Regine WF, Dempsey RJ, Mohiuddin M, Kryscio RJ, et al: Postoperative radiotherapy in the treatment of single metastases to the brain: a randomized trial. **Jama** **280**:1485-1489, 1998
 90. Patchell RA, Tibbs PA, Walsh JW, Dempsey RJ, Maruyama Y, Kryscio RJ, et al: A randomized trial of surgery in the treatment of single metastases to the brain. **N Engl J Med** **322**:494-500, 1990
 91. Percy AK, Elveback LR, Okazaki H, Kurland LT: Neoplasms of the central nervous system. Epidemiologic considerations. **Neurology** **22**:40-48, 1972
 92. Petrovich Z, Yu C, Giannotta SL, O'Day S, Apuzzo ML: Survival and pattern of failure in brain metastasis treated with stereotactic gamma knife radiosurgery. **J Neurosurg** **97**:499-506, 2002
 93. Phillips TL, Scott CB, Leibel SA, Rotman M, Weigensberg IJ: Results of a randomized comparison of radiotherapy and bromodeoxyuridine with radiotherapy alone for brain metastases: report of RTOG trial 89-05. **Int J Radiat Oncol Biol Phys** **33**:339-348, 1995
 94. Pirzkall A, Debus J, Lohr F, Fuss M, Rhein B, Engenhart-Cabillic R, et al: Radiosurgery alone or in combination with whole-brain radiotherapy for brain metastases. **J Clin Oncol** **16**:3563-3569, 1998
 95. Posner JB: Brain metastases: 1995. A brief review. **J Neurooncol** **27**:287-293, 1996
 96. Postmus PE, Smit EF: Chemotherapy for brain metastases of lung cancer: a review. **Ann Oncol** **10**:753-759, 1999
 97. Quinn JA, DeAngelis LM: Neurologic emergencies in the cancer patient. **Semin Oncol** **27**:311-321, 2000
 98. Rades D, Bohlen G, Pluemer A, Veninga T, Hanssens P, Dunst J, et al: Stereotactic radiosurgery alone versus resection plus whole-brain radiotherapy for 1 or 2 brain metastases in recursive partitioning analysis class 1 and 2 patients. **Cancer** **109**:2515-2521, 2007
 99. Ransohoff J: Surgical management of metastatic tumors. **Semin Oncol** **2**:21-27, 1975
 100. Richards GM, Khuntia D, Mehta MP: Therapeutic management of metastatic brain tumors. **Crit Rev Oncol Hematol** **61**:70-78, 2007
 101. Rogers LR, Rock JP, Sills AK, Vogelbaum MA, Suh JH, Ellis TL, et al: Results of a phase II trial of the GliaSite radiation therapy system for the treatment of newly diagnosed, resected single brain metastases. **J Neurosurg** **105**:375-384, 2006
 102. Sabatier J, Ibarrola D, Malet-Martino M, Berry I: [Brain tumors: interest of magnetic resonance spectroscopy for the diagnosis and the prognosis]. **Rev Neurol (Paris)** **157**:858-862, 2001
 103. Samlowski WE, Watson GA, Wang M, Rao G, Klimo P, Jr., Boucher K, et al: Multimodality treatment of melanoma brain metastases incorporating stereotactic radiosurgery (SRS). **Cancer** **109**:1855-1862, 2007
 104. Sanghavi SN, Miranpuri SS, Chappell R, Buatti JM, Sneed PK, Suh JH, et al: Radiosurgery for patients with brain metastases: a multi-institutional analysis, stratified by the RTOG recursive partitioning analysis method. **Int J Radiat Oncol Biol Phys** **51**:426-434, 2001
 105. Sansur CA, Chin LS, Ames JW, Banegura AT, Aggarwal S, Ballesteros M, et al: Gamma knife radiosurgery for the treatment of brain metastases. **Stereotact Funct Neurosurg** **74**:37-51, 2000
 106. Sawaya R, Bindal RK, Lang FF, Abi-said D: **Metastatic Brain Tumors**, ed 2nd ed. New York: Churchill Livingstone, 2001
 107. Sawaya R, Ligon BL, Bindal RK: Management of metastatic brain tumors. **Ann Surg Oncol** **1**:169-178, 1994
 108. Schouten LJ, Rutten J, Huveneers HA, Twijnstra A: Incidence of brain metastases in a cohort of patients with carcinoma of the breast, colon, kidney, and lung and melanoma. **Cancer** **94**:2698-2705, 2002
 109. Serizawa T, Ono J, Ichi T, Matsuda S, Sato M, Odaki M, et al: Gamma knife radiosurgery for metastatic brain tumors from lung cancer: a comparison between small cell and non-small cell carcinoma. **J Neurosurg** **97**:484-488, 2002
 110. Shapiro WR, Mehta MP, Patchell RA: Motexafin gadolinium (MGd) combined with whole brain radiation therapy prolongs time to neurologic progression in non-small cell lung cancer (NSCLC) patients with brain metastases: pooled analysis of two randomized phase 3 trials. **Neurooncology** **8**:489, 2006
 111. Shaw E, Scott C, Souhami L, Dinapoli R, Kline R, Loeffler J, et al: Single dose radiosurgical treatment of recurrent previously irradiated primary brain tumors and brain metastases: final report of RTOG protocol 90-05. **Int J Radiat Oncol Biol Phys** **47**:291-298, 2000
 112. Sheehan JP, Sun MH, Kondziolka D, Flickinger J, Lunsford LD: Radiosurgery for non-small cell lung carcinoma metastatic to the brain: long-term outcomes and prognostic factors influencing patient survival time and local tumor control. **J Neurosurg** **97**:1276-1281, 2002
 113. Shehata MK, Young B, Reid B, Patchell RA, St Clair W, Sims J, et al: Stereotactic radiosurgery of 468

- brain metastases \leq 2 cm: implications for SRS dose and whole brain radiation therapy. **Int J Radiat Oncol Biol Phys** **59**:87-93, 2004
114. Siker ML, Mehta MP: Resection versus radiosurgery for patients with brain metastases. **Future Oncol** **3**:95-102, 2007
 115. Simonova G, Liscak R, Novotny J Jr., Novotny J: Solitary brain metastases treated with the Leksell gamma knife: prognostic factors for patients. **Radiother Oncol** **57**:207-213, 2000
 116. Smalley SR, Laws ER Jr., O'Fallon JR, Shaw EG, Schray MF: Resection for solitary brain metastasis. Role of adjuvant radiation and prognostic variables in 229 patients. **J Neurosurg** **77**:531-540, 1992
 117. Sneed PK, Lamborn KR, Forstner JM, McDermott MW, Chang S, Park E, et al: Radiosurgery for brain metastases: is whole brain radiotherapy necessary? **Int J Radiat Oncol Biol Phys** **43**:549-558, 1999
 118. Sneed PK, Suh JH, Goetsch SJ, Sanghavi SN, Chappell R, Buatti JM, et al: A multi-institutional review of radiosurgery alone vs. radiosurgery with whole brain radiotherapy as the initial management of brain metastases. **Int J Radiat Oncol Biol Phys** **53**:519-526, 2002
 119. Soffiatti R, Ruda R, Mutani R: Management of brain metastases. **J Neurol** **249**:1357-1369, 2002
 120. Sturm V, Kober B, Hover KH, Schlegel W, Boesecke R, Pastyr O, et al: Stereotactic percutaneous single dose irradiation of brain metastases with a linear accelerator. **Int J Radiat Oncol Biol Phys** **13**:279-282, 1987
 121. Szeifert GT, Massager N, DeVriendt D, David P, De Smedt F, Rorive S, et al: Observations of intracranial neoplasms treated with gamma knife radiosurgery. **J Neurosurg** **97**:623-626, 2002
 122. Tajran D, Berek JS: Surgical resection of solitary brain metastasis from cervical cancer. **Int J Gynecol Cancer** **13**:368-370, 2003
 123. van de Pol M, van Aalst VC, Wilmink JT, Twijnstra A: Brain metastases from an unknown primary tumour: which diagnostic procedures are indicated? **J Neurol Neurosurg Psychiatry** **61**:321-323, 1996
 124. Varlotto JM, Flickinger JC, Niranjana A, Bhatnagar AK, Kondziolka D, Lunsford LD: Analysis of tumor control and toxicity in patients who have survived at least one year after radiosurgery for brain metastases. **Int J Radiat Oncol Biol Phys** **57**:452-464, 2003
 125. Vecht CJ, Haaxma-Reiche H, Noordijk EM, Padberg GW, Voormolen JH, Hoekstra FH, et al: Treatment of single brain metastasis: radiotherapy alone or combined with neurosurgery? **Ann Neurol** **33**:583-590, 1993
 126. Verger E, Gil M, Yaya R, Vinolas N, Villa S, Pujol T, et al: Temozolomide and concomitant whole brain radiotherapy in patients with brain metastases: a phase II randomized trial. **Int J Radiat Oncol Biol Phys** **61**:185-191, 2005
 127. Walker AE, Robins M, Weinfeld FD: Epidemiology of brain tumors: the national survey of intracranial neoplasms. **Neurology** **35**:219-226, 1985
 128. Wang LG, Guo Y, Zhang X, Song SJ, Xia JL, Fan FY, et al: Brain metastasis: experience of the Xi-Jing hospital. **Stereotact Funct Neurosurg** **78**:70-83, 2002
 129. Weiss L, Grundmann E, Torhorst J, Hartveit F, Moberg I, Eder M, et al: Haematogenous metastatic patterns in colonic carcinoma: an analysis of 1541 necropsies. **J Pathol** **150**:195-203, 1986
 130. Wen PY, Loeffler JS: Management of brain metastases. **Oncology (Williston Park)** **13**:941-954, 957-961; discussion 961-962, 1999
 131. Wronski M, Arbit E: Resection of brain metastases from colorectal carcinoma in 73 patients. **Cancer** **85**:1677-1685, 1999
 132. Wronski M, Arbit E, Burt M, Galicich JH: Survival after surgical treatment of brain metastases from lung cancer: a follow-up study of 231 patients treated between 1976 and 1991. **J Neurosurg** **83**:605-616, 1995
 133. Yamamoto M: Radiosurgery for metastatic brain tumors. **Prog Neurol Surg** **20**:106-128, 2007
 134. Yamamoto M, Ide M, Nishio S, Urakawa Y: Gamma Knife radiosurgery for numerous brain metastases: is this a safe treatment? **Int J Radiat Oncol Biol Phys** **53**:1279-1283, 2002
 135. York JE, Stringer J, Ajani JA, Wildrick DM, Gokaslan ZL: Gastric cancer and metastasis to the brain. **Ann Surg Oncol** **6**:771-776, 1999

COMPLETE SUMMARY

TITLE:

Stereotactic Radiosurgery for Patients with Metastatic Brain Tumors

RELEASE DATE:

May 2008

DEVELOPER AND FUNDING SOURCE:

International RadioSurgery Association (IRSA)

DEVELOPER COMMENT:

International RadioSurgery Association is an independent entity dedicated to promoting the development of scientifically relevant practice guidelines for stereotactic radiosurgery. IRSA is a professional organization that works to educate and provide support for physicians, hospitals, insurers and patients.

COMMITTEE:

The IRSA Medical Advisory Board Guidelines Committee and representatives in the industry.

GROUP COMPOSITION:

The radiosurgery guidelines group is comprised of neurosurgeons, neuro-oncologists, radiation and medical oncologists and physicists.

Names of Group Members: Ajay Niranjana, M.B.B.S., M.Ch., Neurosurgeon, Chair; L. Dade Lunsford, M.D., Neurosurgeon; Richard L. Weiner, M.D., Neurosurgeon; Gail L. Rousseau, M.D., Neurosurgeon; Gene H. Barnett, M.D., F.A.C.S., Neurosurgeon; Massaki Yamamoto, M.D.

Neurosurgeon; Lawrence S. Chin, M.D., F.A.C.S., Neurosurgeon; Paul J. Miller, M.D., Radiation Oncologist; Andrew E. Sloan, M.D., Neurosurgeon; Burton L. Speiser, M.D., Radiation Oncologist; Sandra S. Vermeulen, M.D., Radiation Oncologist; Harish Thakrar, M.D., Radiation Oncologist; Frank Lieberman, M.D., Neuro-Oncologist; David Schiff, M.D., Neuro-Oncologist; Sammie R. Coy, Ph.D., Medical Physicist; Tonya K. Ledbetter, M.S., M.F.S., Editor; Rebecca L. Emerick, M.S., M.B.A., C.P.A., ex officio.

DISEASE/CONDITION:

Brain metastases

NUMBER OF REFERENCES:

135

CATEGORY:

Treatment, proposed management, radiosurgery

CLINICAL SPECIALTY:

Neurological surgery
Neurology
Medical oncology
Radiation oncology

INTENDED USERS:

Physicians
Health Care Providers
Hospitals
Managed Care Organizations
Medical Physicists
Nurses
Utilization Management

OBJECTIVES:

To develop an evidence and consensus-based stereotactic radiosurgery practice guideline for radiosurgery treatment recommendations to be used by medical and public health professionals following the diagnosis of brain metastatic disease.

TARGET POPULATION:

Patients diagnosed with metastatic brain disease.

INTERVENTIONS AND PRACTICES:

The management options for brain metastatic disease include careful serial observation, surgical removal, radiosurgery, whole-brain radiation therapy and chemotherapy. Stereotactic radiosurgery is the preferred management approach for patients with small to moderate tumor size.

Follow-up after stereotactic radiosurgery of the brain metastases is performed using the following schedules:

- Assess MRI scans for tumor response every 2–3 months for one year, then every 4–6 months.

OUTCOMES CONSIDERED:

Tumor growth control, overall survival, new tumors, functional improvement, adverse events, quality of life and overall patient satisfaction.

METHODS TO COLLECT EVIDENCE:

Hand searches of published literature (primary sources); hand searches of published literature (secondary sources); searches of electronic databases

DESCRIPTION OF METHODS TO COLLECT EVIDENCE:

MEDLINE and PUBMED searches were completed for the years 1966 to May 2008. Search terms included: brain metastases, metastatic brain tumor, stereotactic radiosurgery, Gamma Knife,[®] linear accelerator, irradiation, clinical trials, research design, practice guidelines and meta-analysis. Bibliographies from recent published reviews were reviewed and relevant articles were retrieved.

METHODS TO ASSESS THE QUALITY AND STRENGTH OF THE EVIDENCE:

Expert consensus (committee)

METHODS TO ANALYZE EVIDENCE:

Review of published meta-analysis

REVIEW METHODS:

External peer review; internal peer review

DESCRIPTION OF REVIEW METHODS:

The recommendations were a synthesis of research obtained in the evidence gathering process by a core group of two members (AN and LDL). These recommendations were mailed to all committee members. Feedback was obtained through this mailed survey consisting of proposed guidelines asking for comments on the guidelines and whether the recommendation should serve as a practice guideline. No significant disagreements existed. The final statement incorporates all relevant evidence obtained by the literature search in conjunction with the final consensus recommendations supported by all working group members.

MAJOR RECOMMENDATIONS:

- Patients with brain metastases, defined by modern neurodiagnostic imaging (CT, MRI scan) constitute the study group. Such patients typically present with seizures or symptoms of mass effects such as headache, nausea, vomiting, weakness, numbness of limbs or speech problems. Many patients' tumors are detected due to MRI surveillance before they develop any symptoms.
- Stereotactic radiosurgery is a minimally invasive, single session, high-dose, closed skull strategy that may be especially suitable for patients who have limited metastatic brain disease and have controlled systemic disease with good functional status.

- Stereotactic radiosurgery is typically employed alone or as a boost after WBRT for patients with metastatic brain tumors.
- A high resolution double dose contrast-enhanced MR imaging is usually necessary to determine the number of metastatic tumors. For radiosurgery dose planning, double dose contrast-enhanced volumetric gradient recalled MR stereotactic images are ideal.
- Current radiation delivery technologies for volumetric stereotactic conformal single session radiosurgery include Gamma Knife,[®] proton beam using Bragg peak effect, and specially modified or dedicated linear accelerators like Novalis Tx[™] and Axesse.[™]
- The optimal dose range for volumetric conformal stereotactic brain metastases radiosurgery has been largely established based on tumor anatomy (proximity to eloquent brain regions), tumor volume, prior radiation therapy and estimated adverse radiation risks. Minimum doses to the margin typically range from 14–24 Gy in a single session.
- Patients may receive a single stress dose of corticosteroids at the conclusion of the radiosurgery procedure. Patients can continue to take other medications (antiseizure or antiedema drugs) as recommended by their physicians.
- Post-radiosurgical clinical examinations and MR studies are requested by referring physicians at 2–3 month intervals or earlier if the patient develops a new symptom suggestive of a new tumor, brain edema or hemorrhage.
- Patients with large tumors causing symptomatic mass effect may need surgical decompression of the tumor. Residual tumor or tumor bed can be treated by radiosurgery or radiation therapy.
- Causes for local failure of stereotactic radiosurgery include inadequate visualization of the tumor, lack of intraoperative stereotactic 3-D (volumetric) imaging, new metastatic deposits and insufficient dose (due to large tumor volume and proximity to eloquent brain locations) to achieve the growth control response.

TYPE OF EVIDENCE:

Types I, II and III evidence exist in support of stereotactic radiosurgery for brain metastases.

POTENTIAL BENEFITS:

Minimally invasive approach
High rates of tumor growth control (80–90%)

SUBGROUP(S) MOST LIKELY TO BENEFIT:

Patients diagnosed with small to medium size brain metastases without symptomatic brain compression. Patients with residual or recurrent brain metastases after resection. Patients with residual or recurrent brain metastases after WBRT.

POTENTIAL HARMS:

Major adverse effects of radiosurgery are based on location, volume, and dose, and these risks can be estimated based on published data and experience. Individual risks are related to the anatomic location of tumors.

SUBGROUP(S) LIKELY TO BE HARMED:

Patients with large volume tumors causing symptomatic mass effect on the brain.

GUIDELINE STATUS:

This is the full current release of the guideline.

GUIDELINE AVAILABILITY:

Electronic copies: available in Portable Document Format (PDF) from www.IRSA.org/guidelines.html

PATIENT RESOURCES:

Patient resources are available online at www.IRSA.org, by e-mail at office1@IRSA.org, or by calling +717-260-9808.

See “publications” for patient resources for metastatic brain tumors: www.IRSA.org/publications.html
Brain Talk[®] Volume 5, No. 2

COPYRIGHT STATEMENT:

Copyright IRSA 2008